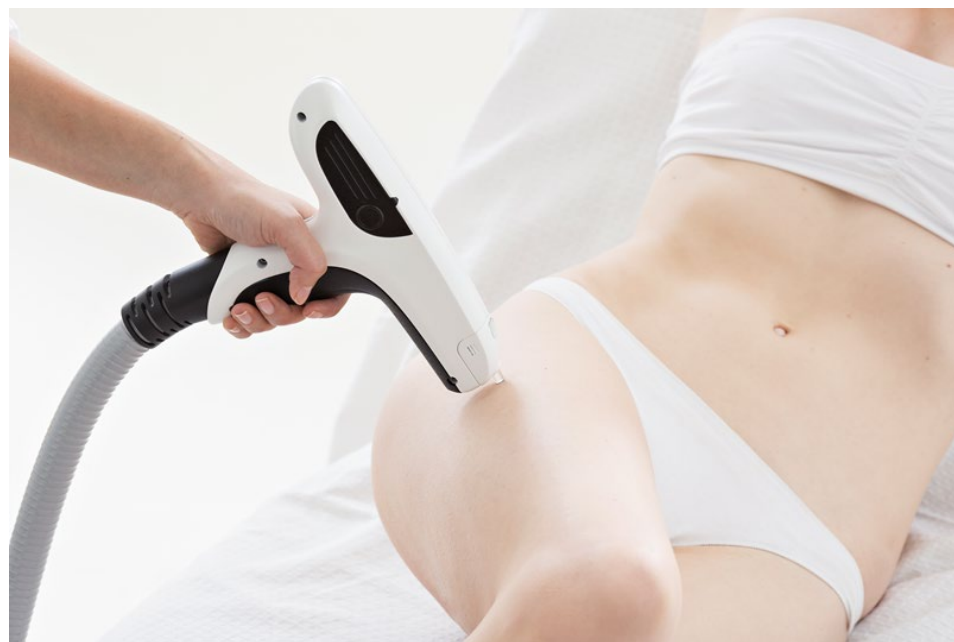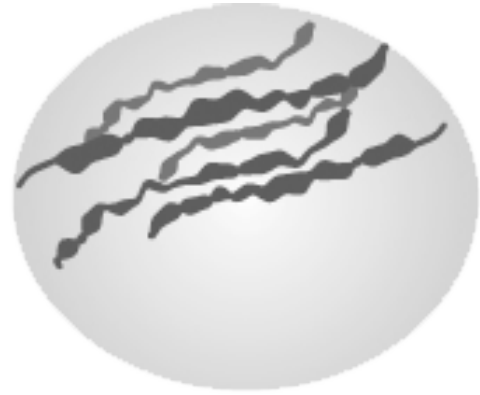


# V·Nd:YAG

## Case Studies



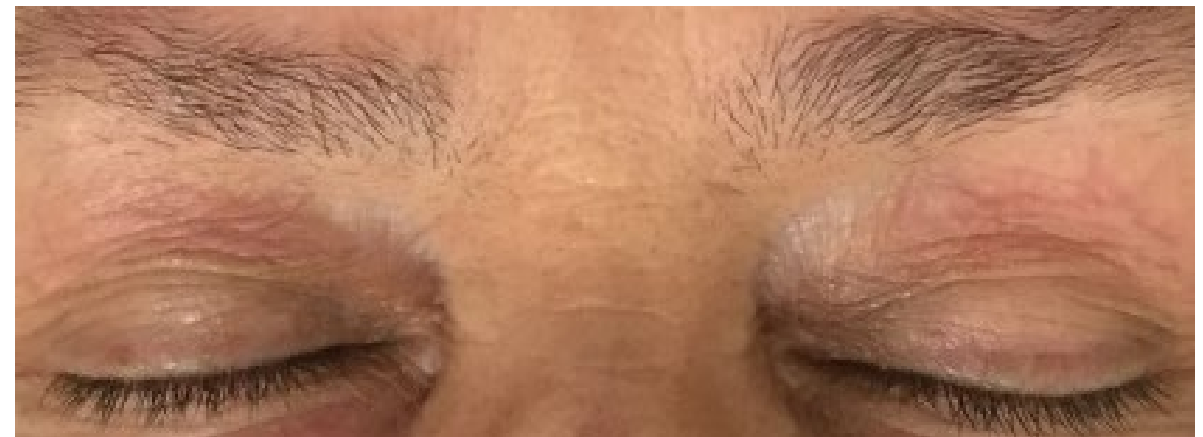
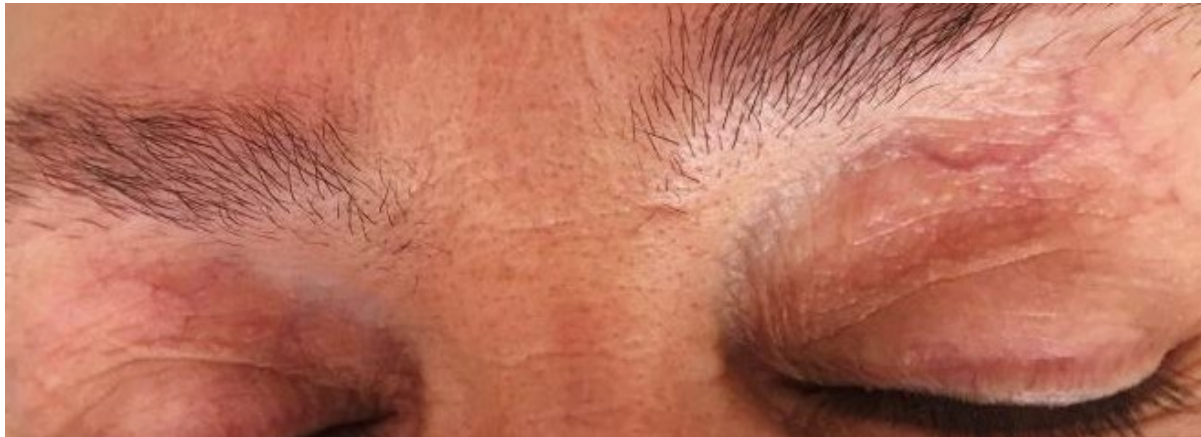
# Vascular Lesions



# Eyelids Telangiectasia

|                             |                                      |
|-----------------------------|--------------------------------------|
| <b>Case Study – VNd#027</b> | <b>Dr. Tzachi Shelkovitz, Israel</b> |
| Patient                     | Female, 70 years old                 |
| Number of Treatments        | <b>1 V-Nd:YAG</b> (5.5 mm spot size) |



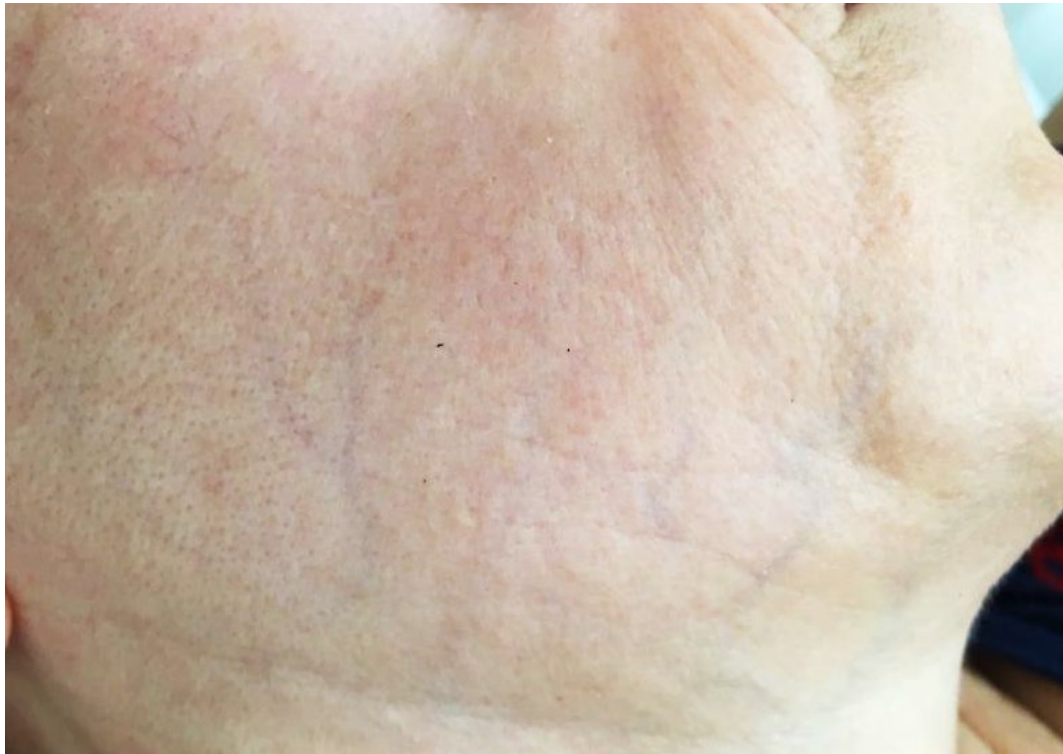Before

4 weeks after

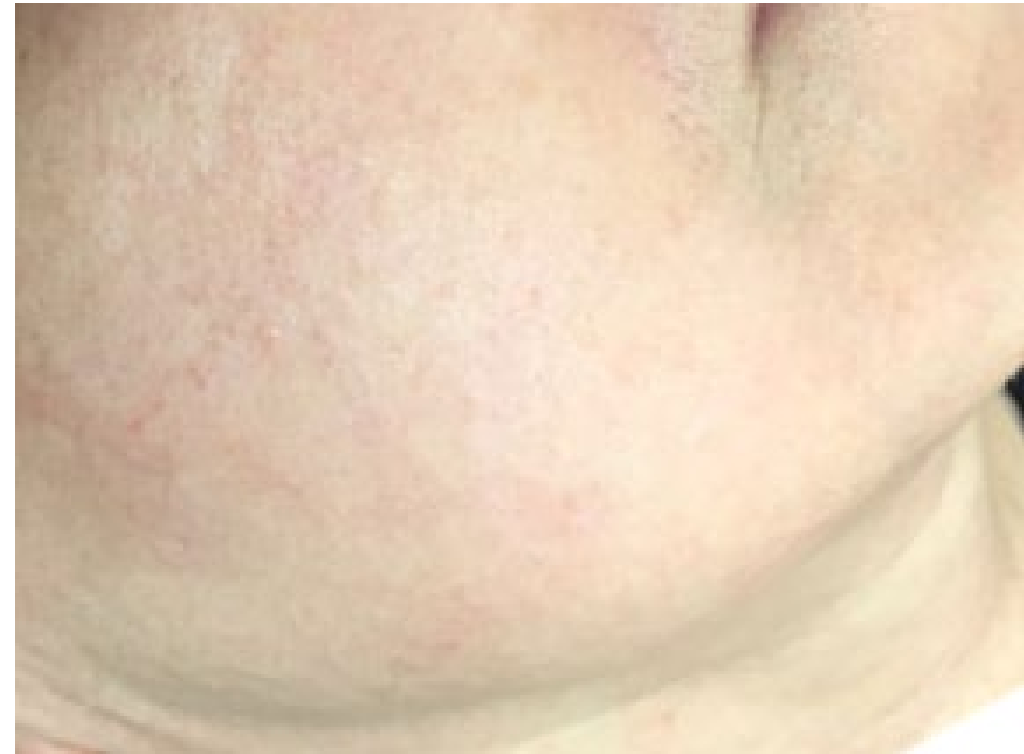

# Facial veins

|                             |                                      |
|-----------------------------|--------------------------------------|
| <b>Case Study – VNd#028</b> | <b>Dr. Tzachi Shelkovitz, Israel</b> |
| Patient                     | Female, 70 years old                 |
| Number of Treatments        | <b>1 V-Nd:YAG</b> (5.5 mm spot size) |



Before

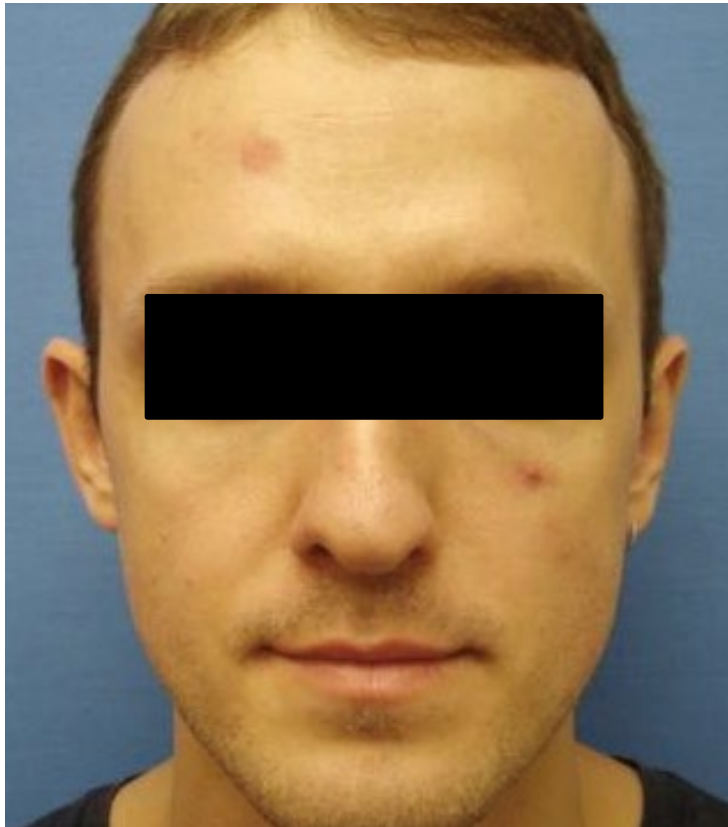

4 weeks After

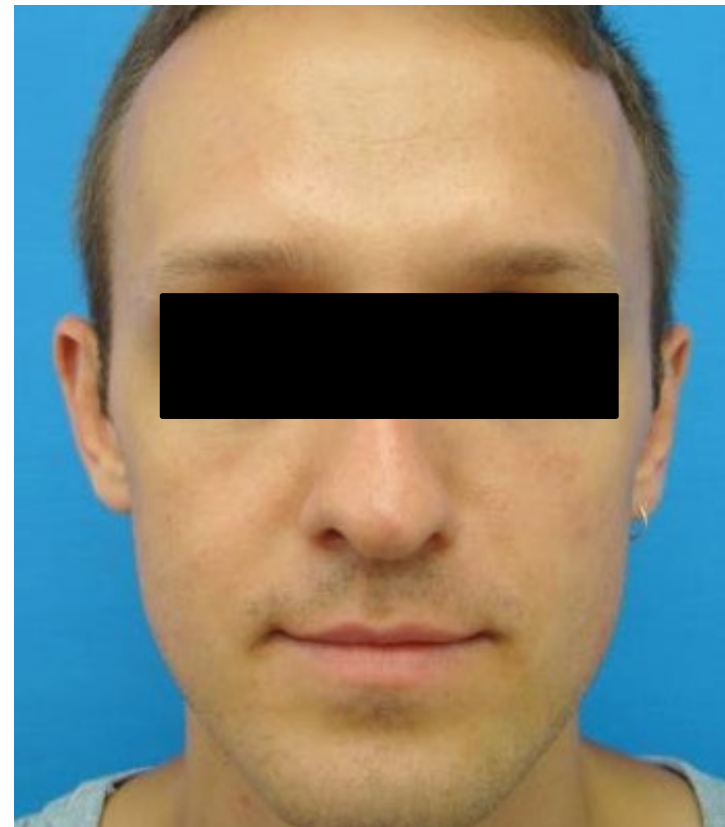

# Vascular lesions

|                             |  |
|-----------------------------|--|
| <b>Case Study – VNd#030</b> | <b>Dr. Tzachi Shelkovitz, Israel</b>                           |
| Patient                     | Male, 33 years old   |
| Number of Treatments        | <b>3 V-Nd:YAG</b> (5.5 mm and 2 x 4 mm <sup>2</sup> spot size) |



Before

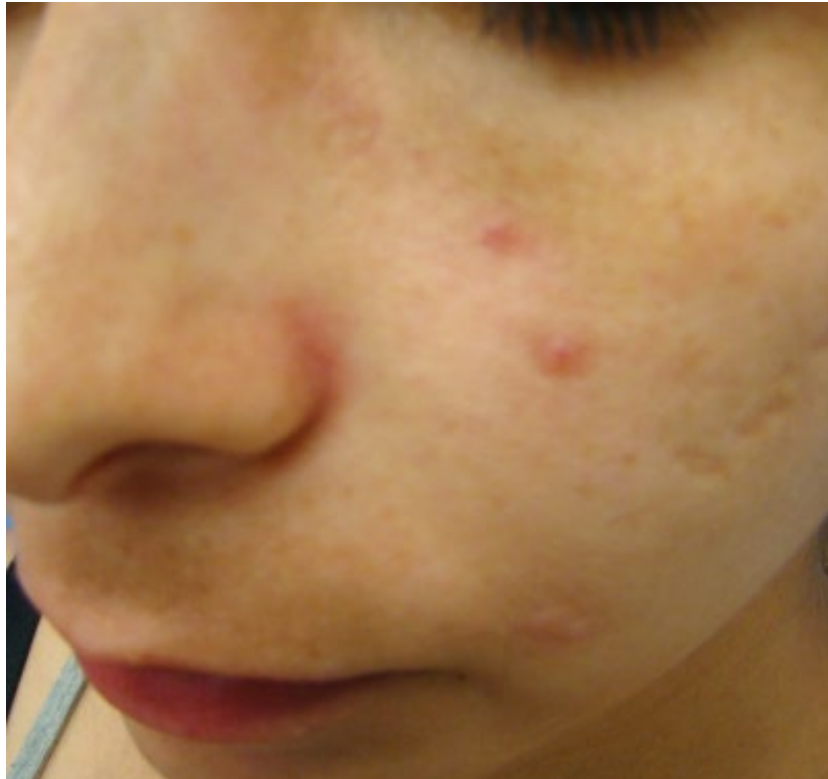

After

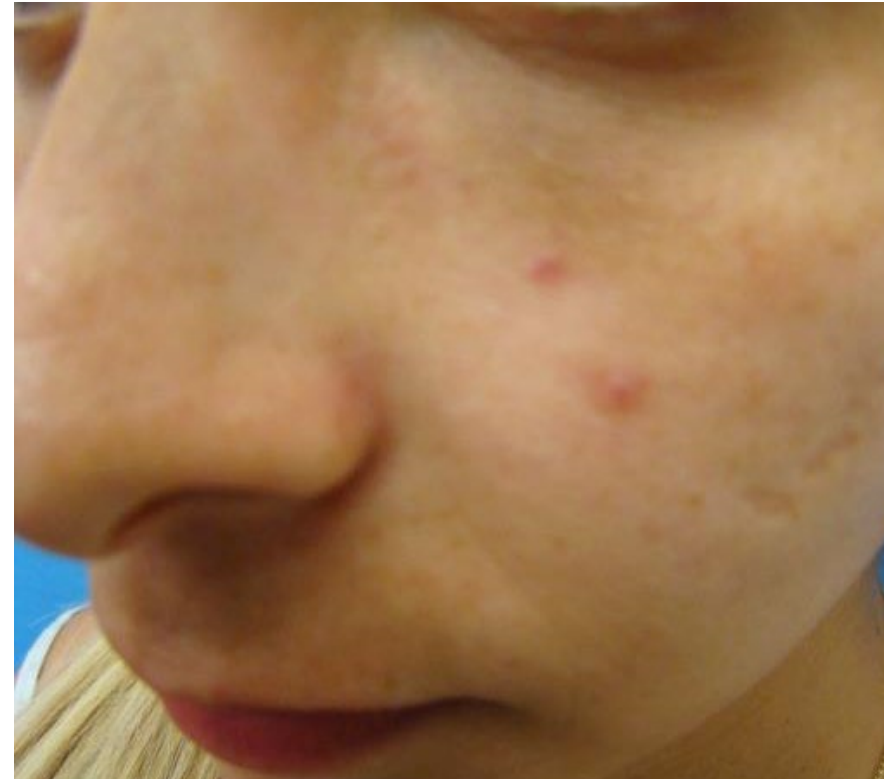

# Facial Telangiectasia

|                             |  |
|-----------------------------|--|
| <b>Case Study – VNd#031</b> | <b>Dr. Tzachi Shelkovitz, Israel</b>                           |
| Patient                     | Female, 31 years old   |
| Number of Treatments        | <b>2 V-Nd:YAG</b> (5.5 mm and 2 x 4 mm <sup>2</sup> spot size) |



Before

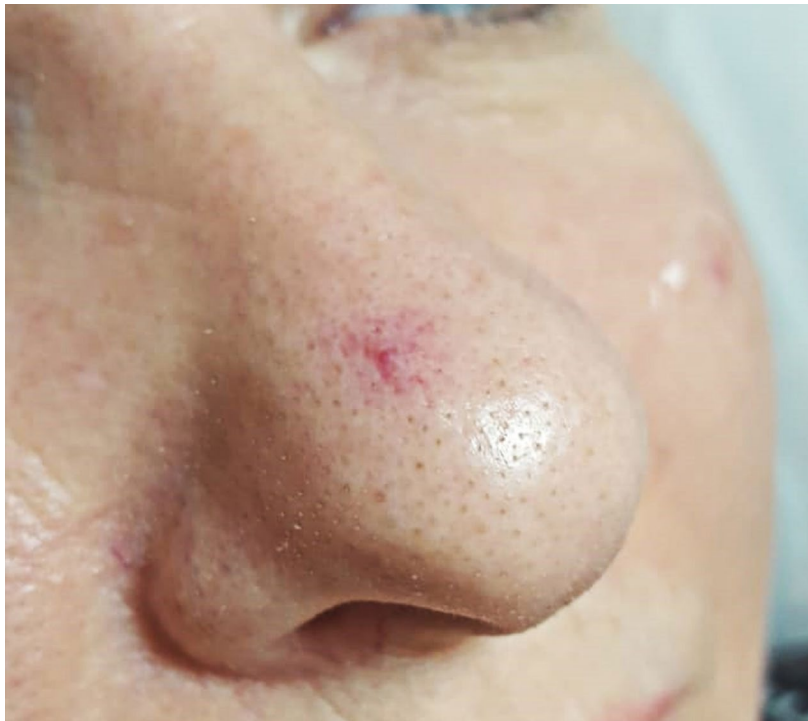

After

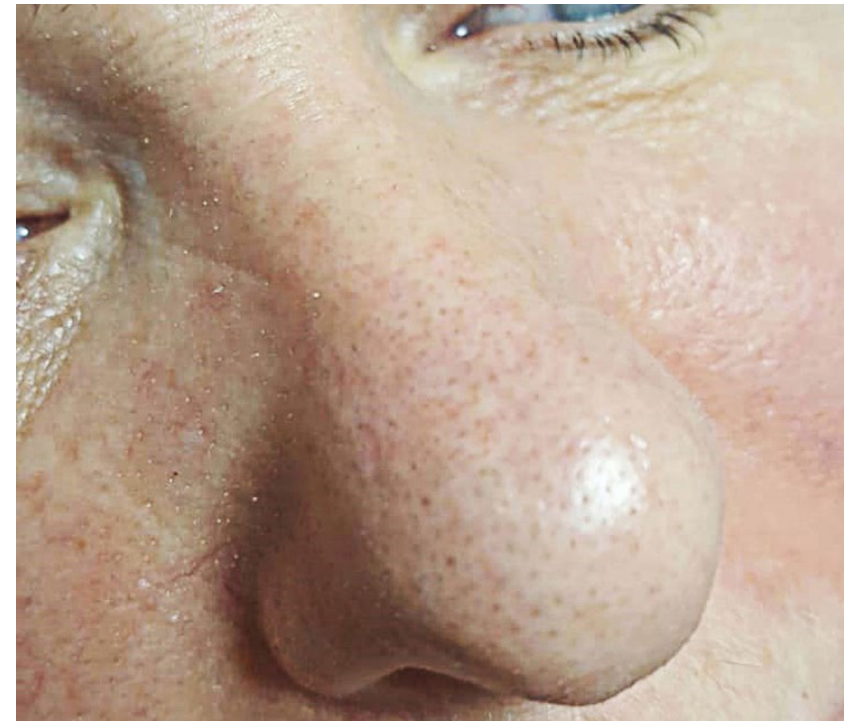

# Facial Telangiectasia

|                             |   |
|-----------------------------|---|
| <b>Case Study – VNd#057</b> | <b>Dr. Natalia Sinizina, Russia</b>               |
| Patient                     | Female  |
| Number of Treatments        | <b>1 V-Nd:YAG</b> (2x4 mm <sup>2</sup> spot size) |



Before

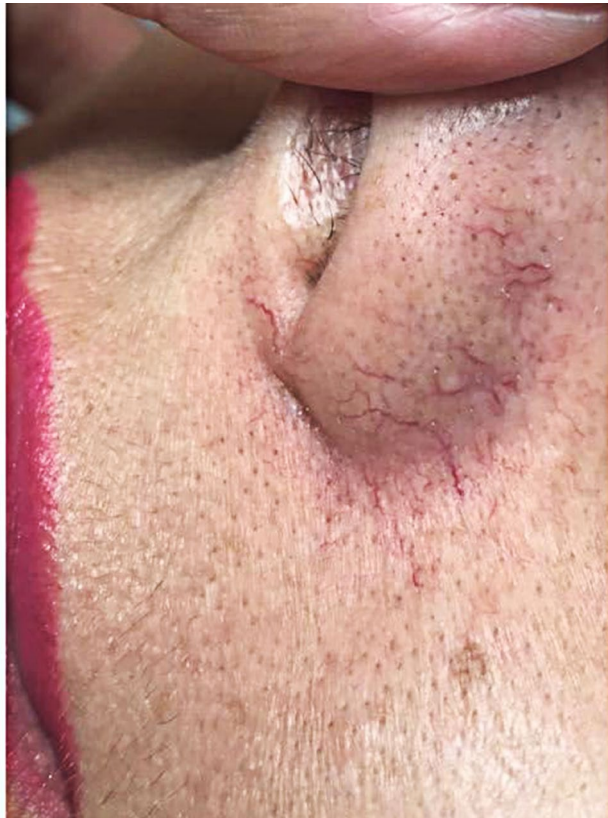

2 Weeks After

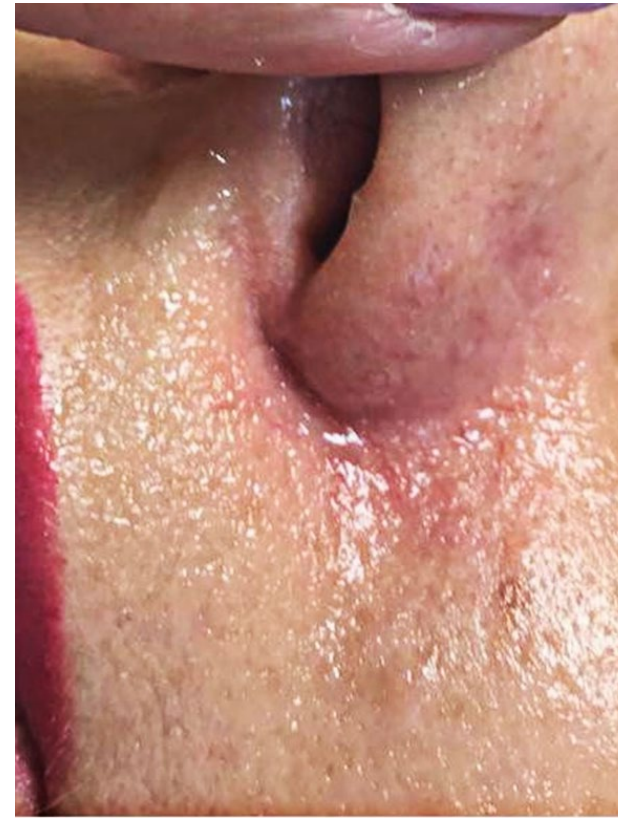

# Facial Telangiectasia

|                             |   |
|-----------------------------|---|
| <b>Case Study – VNd#058</b> | <b>Dr. Anna Kudrina, Russia</b>                   |
| Patient                     | Female  |
| Number of Treatments        | <b>1 V-Nd:YAG</b> (2x4 mm <sup>2</sup> spot size) |



Before



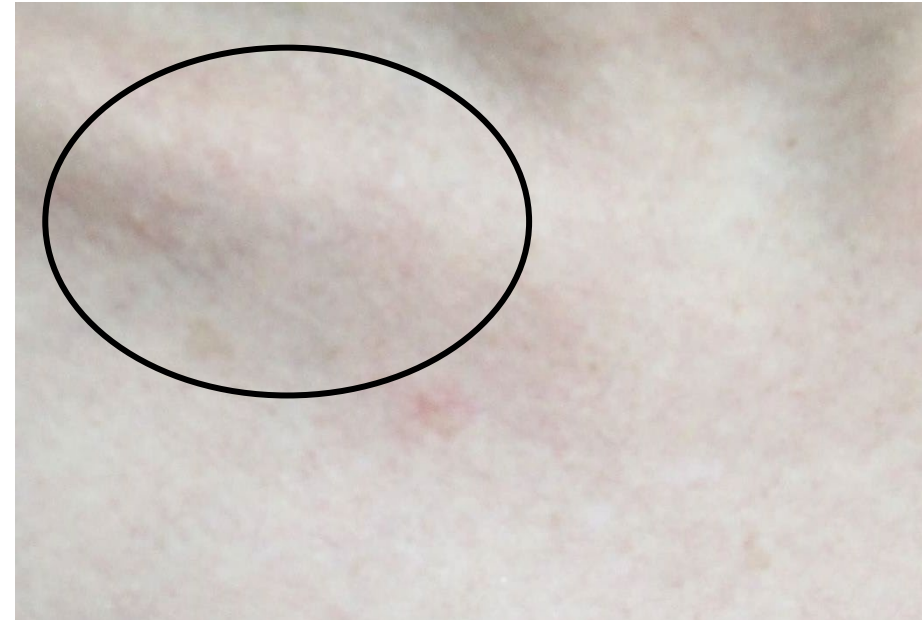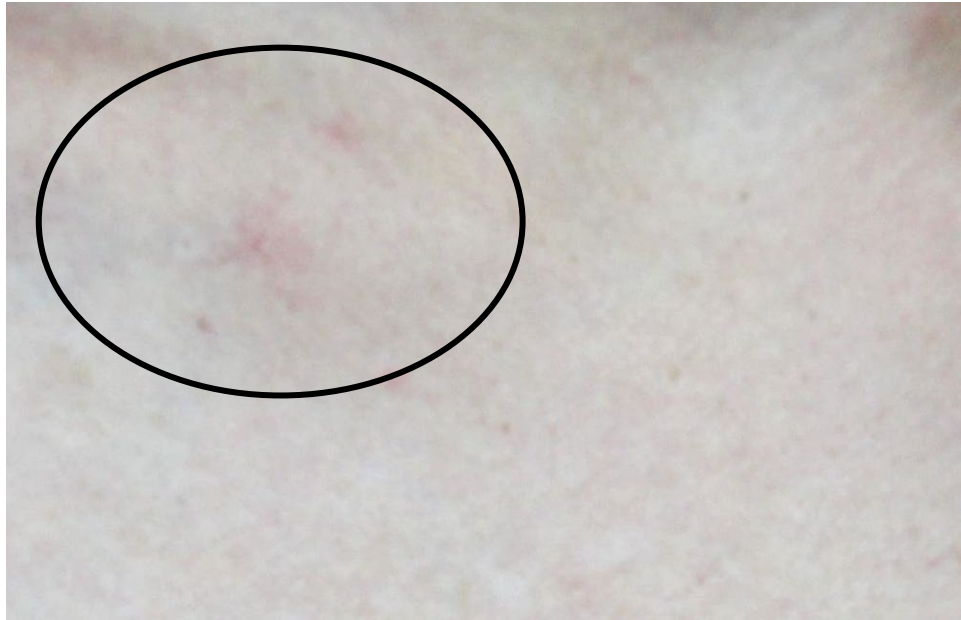After





# Décolleté – Spider veins

|                             |   |
|-----------------------------|---|
| <b>Case Study – VNd#002</b> | <b>Dr. Cruzy Tagger, Viora Ltd.</b>                 |
| Patient                     | Female, 34 years old                                |
| Number of Treatments        | <b>1 V-Nd:YAG</b> (2 x 4 mm <sup>2</sup> spot size) |



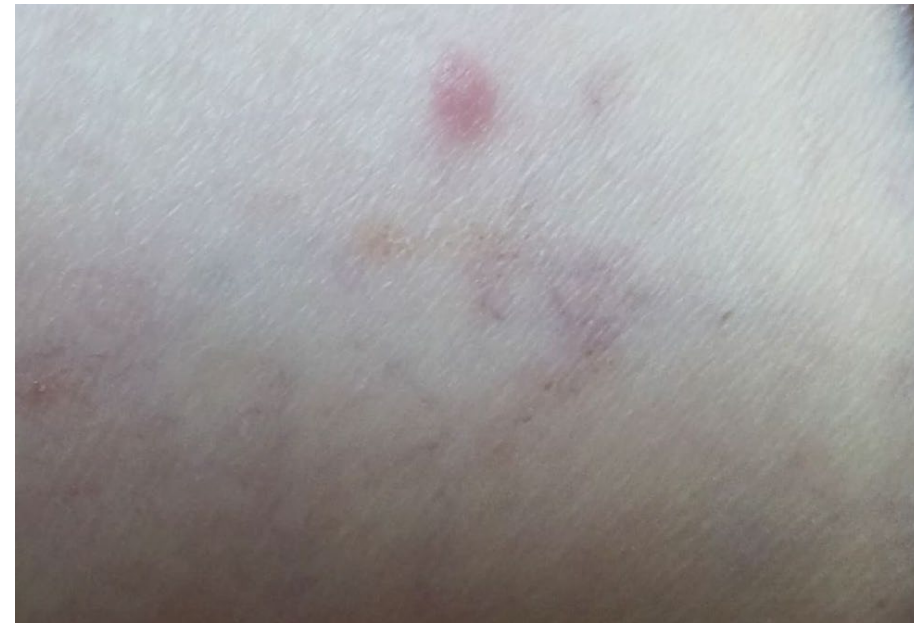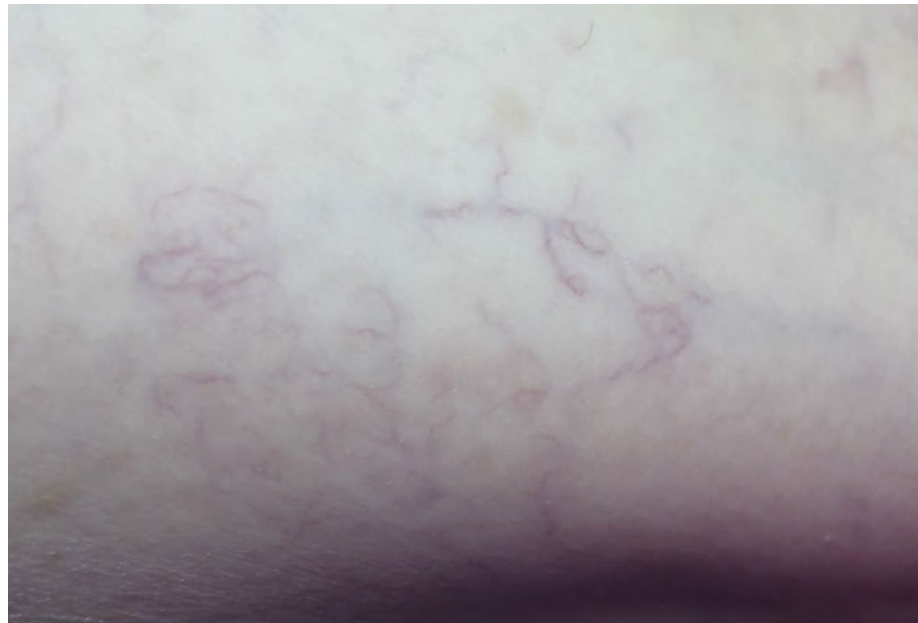Before

After



# Legs – Spider veins

|                             |   |
|-----------------------------|---|
| <b>Case Study – VNd#003</b> | <b>Dr. Cruzy Tagger, Viora Ltd.</b>                 |
| Patient                     | Female, 34 years old                                |
| Number of Treatments        | <b>1 V-Nd:YAG</b> (2 x 4 mm <sup>2</sup> spot size) |



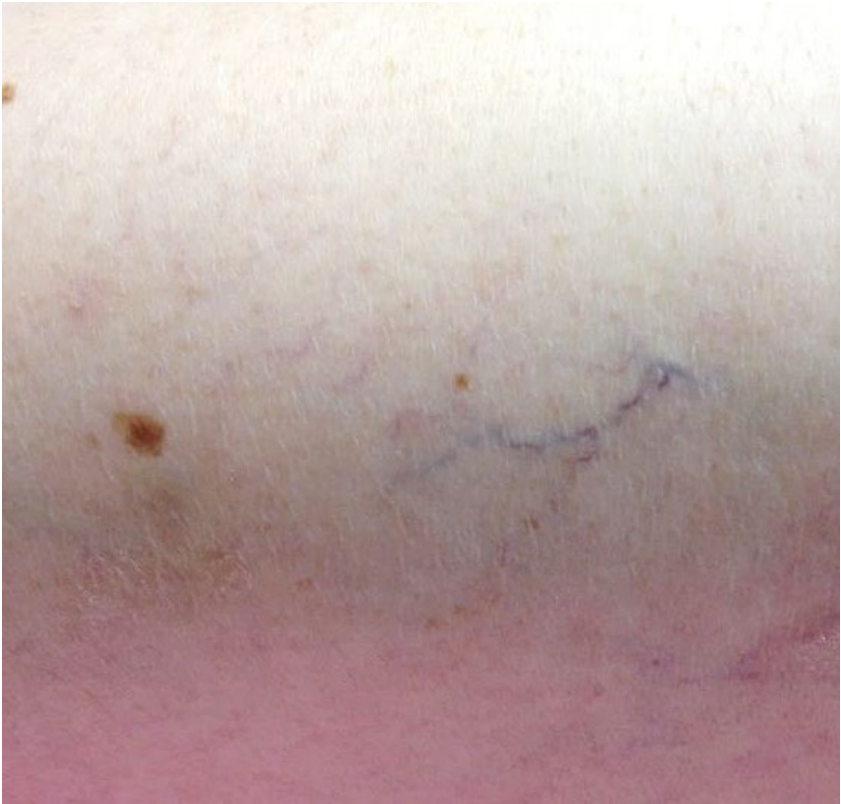Before

After

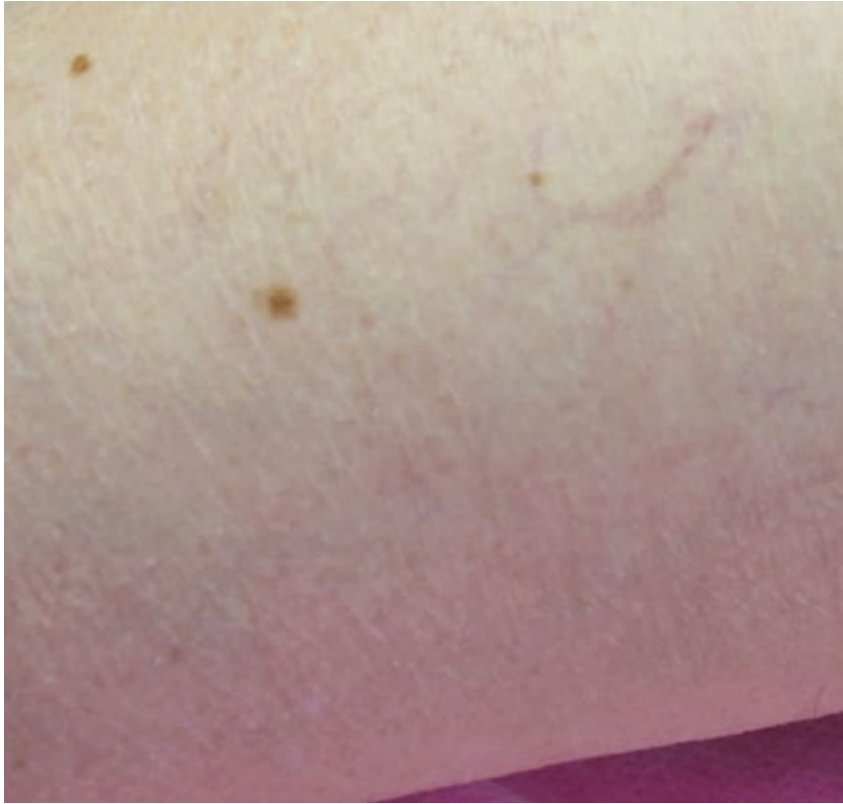

# Spider veins

|                               |   |
|-------------------------------|---|
| <b>Case Study – VNd#007-A</b> | <b>Dr. Cruzy Tagger, Viora Ltd.</b>   |
| Patient                       | Female, 54 years old  |
| Number of Treatments          | <b>1 V-Nd:YAG</b> (2 x 4 mm <sup>2</sup> , 200-210 J/cm <sup>2</sup> , 15 ms, Single) |



Before

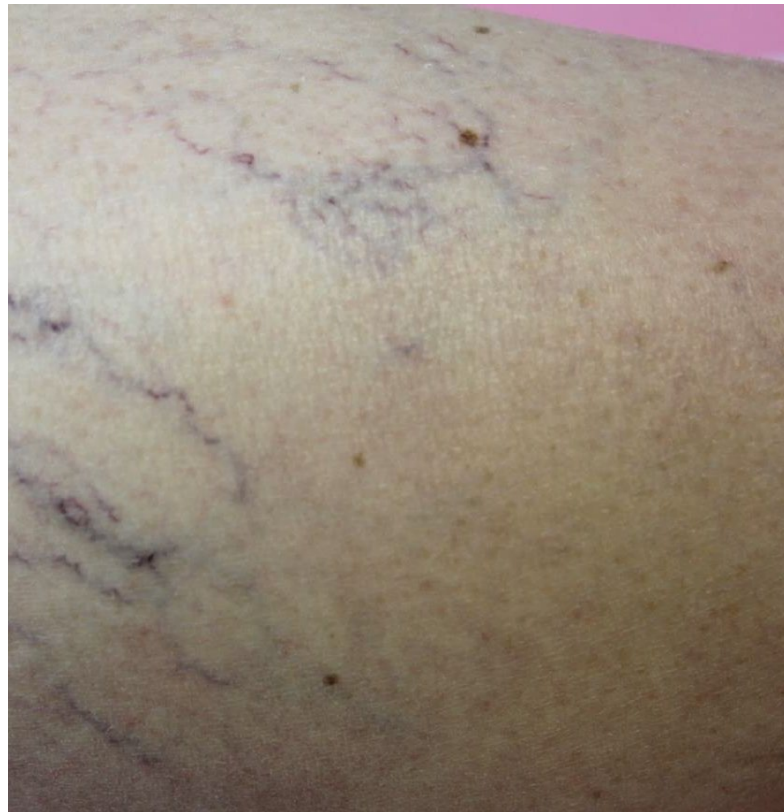

1 month after

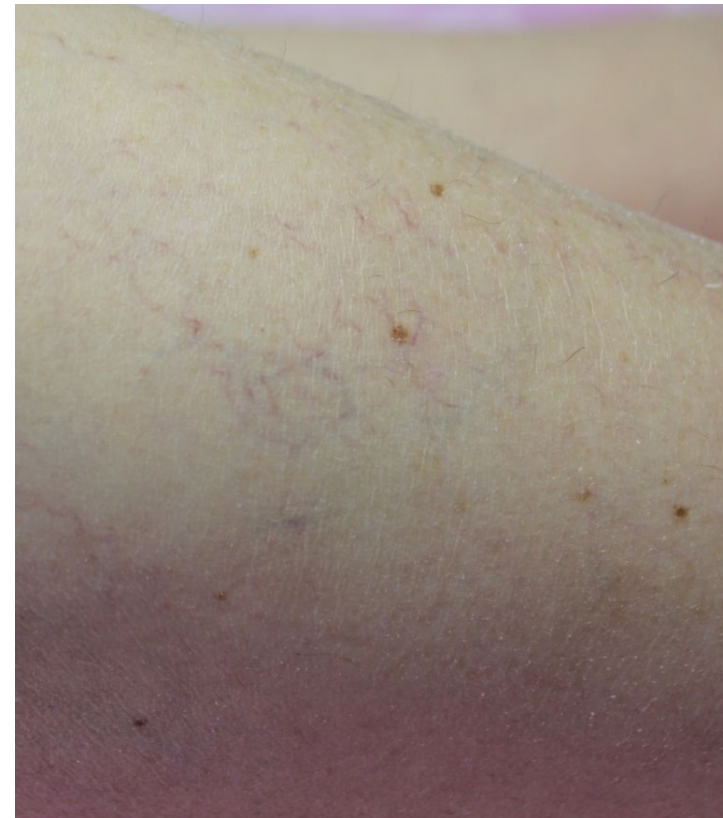

# Spider veins

|                               |                                      |
|-------------------------------|--------------------------------------|
| <b>Case Study – VNd#007-B</b> | <b>Dr. Cruzy Tagger, Viora Ltd.</b>  |
| Patient                       | Female, 54 years old                 |
| Number of Treatments          | <b>2 V-Nd:YAG</b> (3.5 mm spot size) |



Before

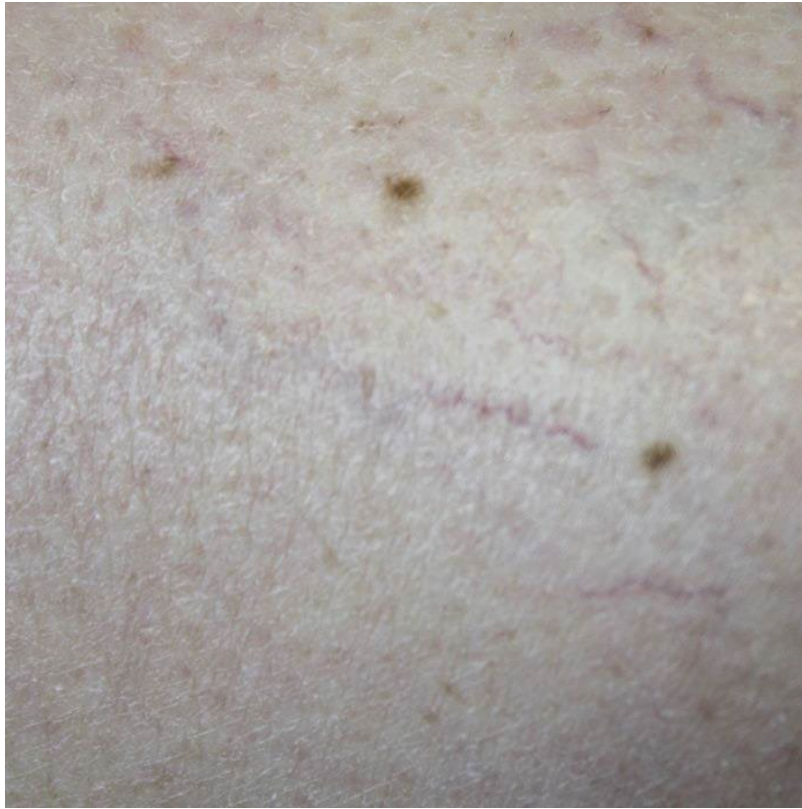

After

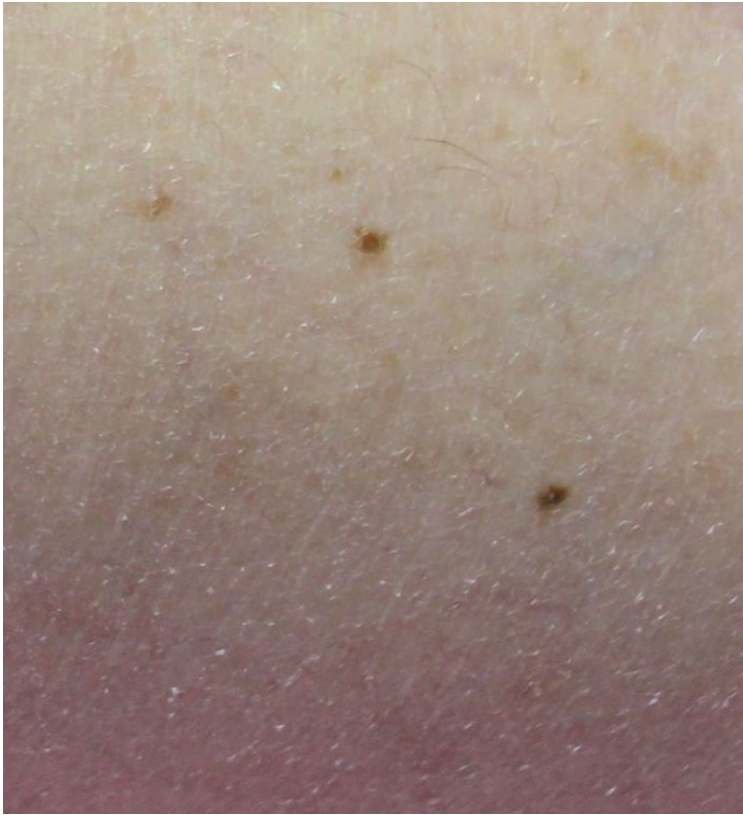

# Spider veins

|                               |                                      |
|-------------------------------|--------------------------------------|
| <b>Case Study – VNd#007-C</b> | <b>Dr. Cruzy Tagger, Viora Ltd.</b>  |
| Patient                       | Female, 54 years old                 |
| Number of Treatments          | <b>2 V-Nd:YAG</b> (3.5 mm spot size) |



Before

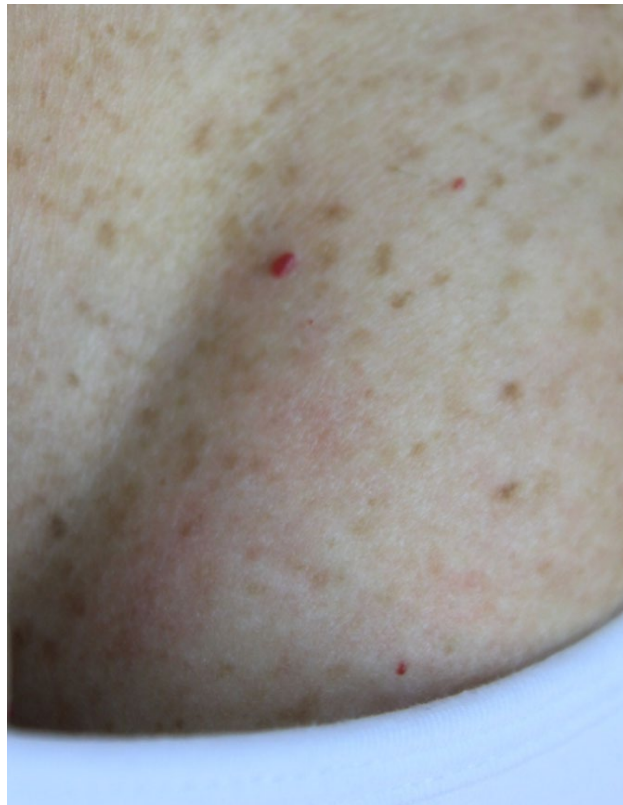


After

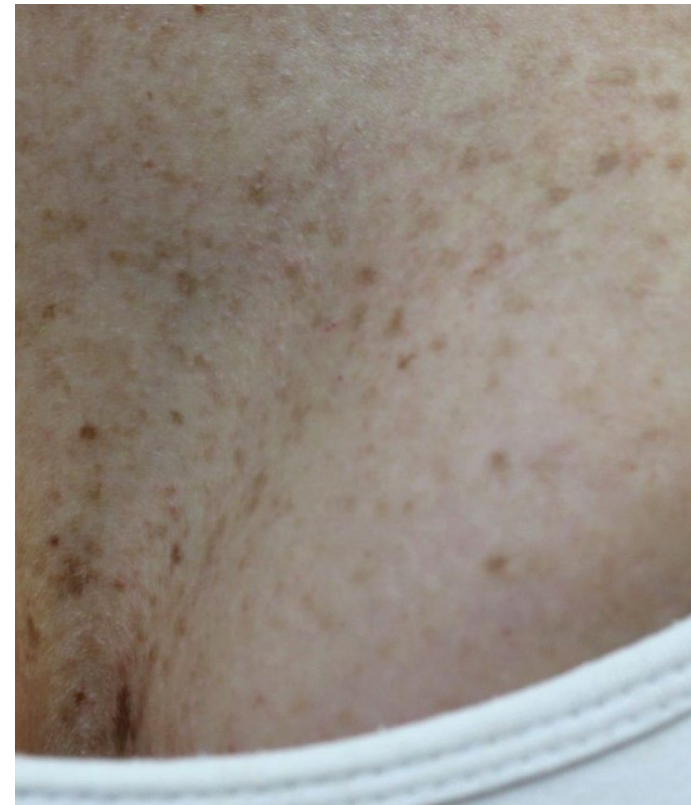

# Hemangioma

|                               |                                      |
|-------------------------------|--------------------------------------|
| <b>Case Study – VNd#008-B</b> | <b>Dr. Cruzy Tagger, Viora Ltd.</b>  |
| Patient                       | Female, 44 years old                 |
| Number of Treatments          | <b>1 V-Nd:YAG</b> (3.5 mm spot size) |



Before

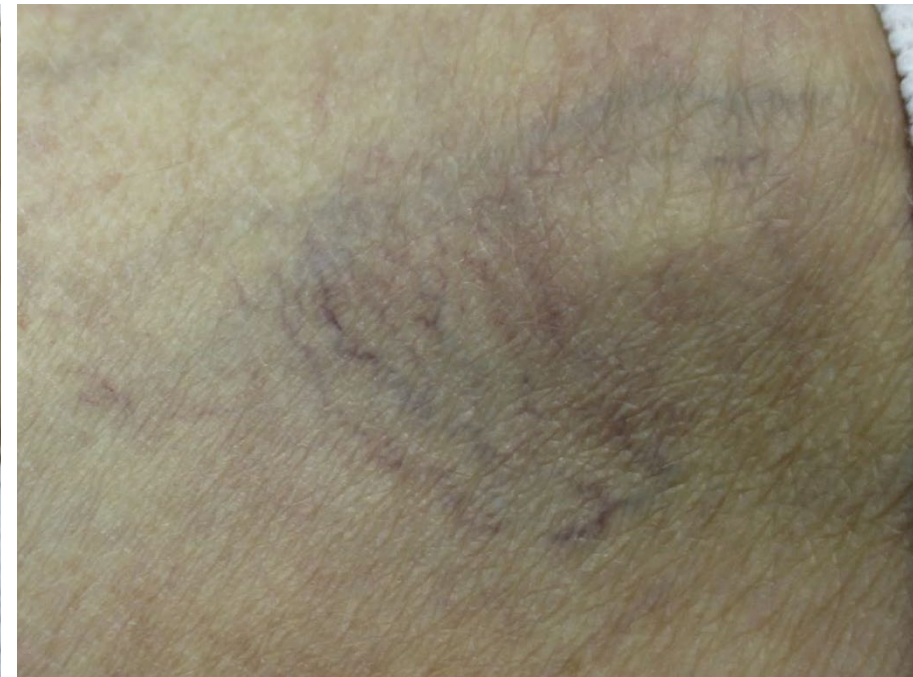
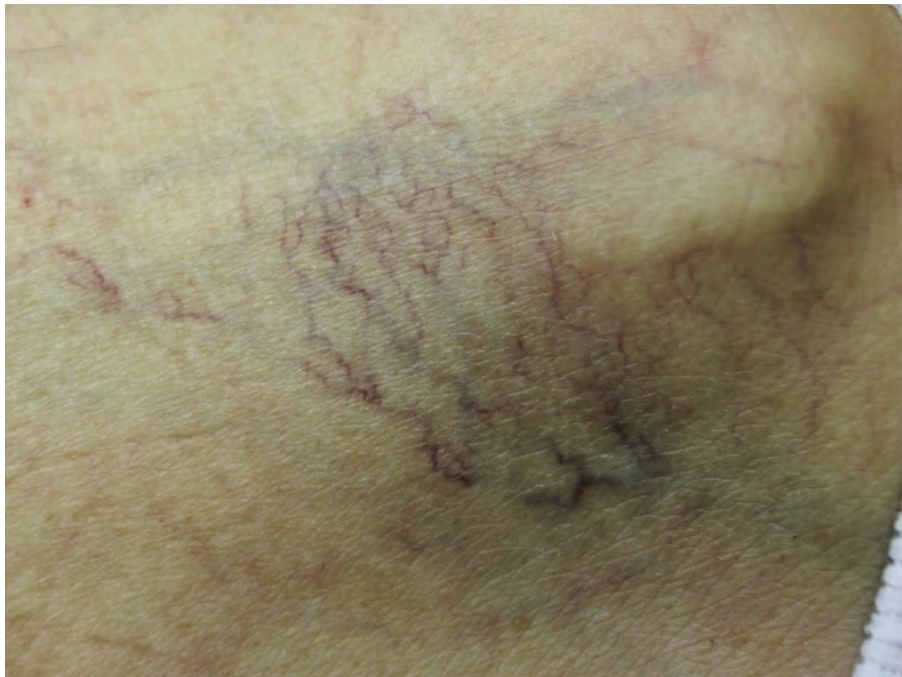
3 months after



# Ankle – Spider veins

|                               |  |
|-------------------------------|--|
| <b>Case Study – VNd#009-A</b> | <b>Dr. Cruzy Tagger, Viora Ltd.</b>  |
| Patient                       | Female, 44 years old   |
| Number of Treatments          | <b>2 V-Nd:YAG</b> (2 x 4 mm <sup>2</sup> spot size, 180-220 J/cm <sup>2</sup> , 15 ms, Single) |



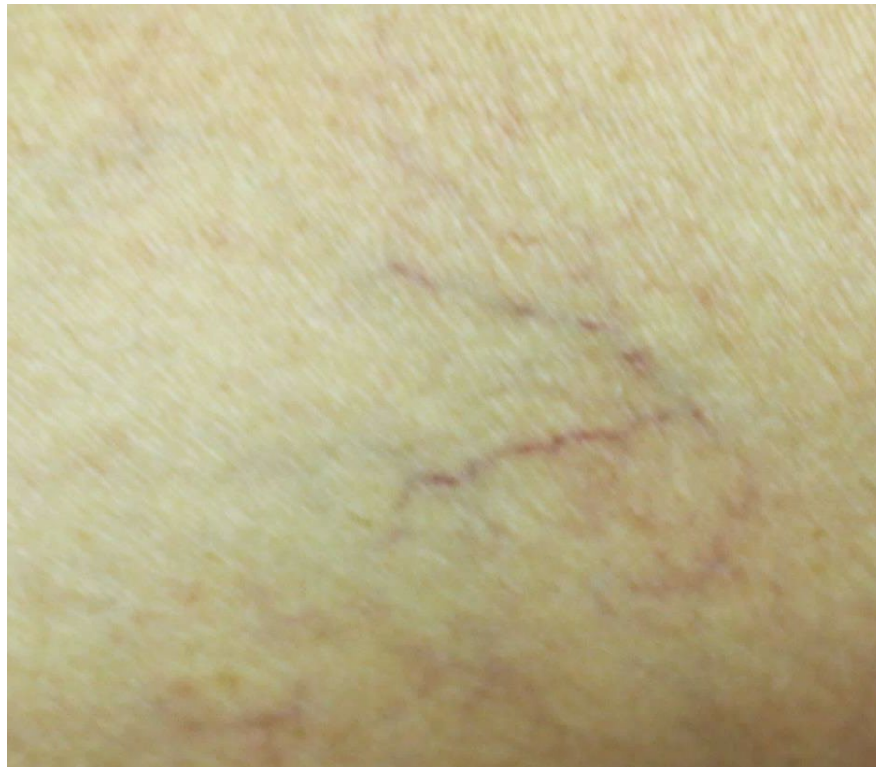Before

After

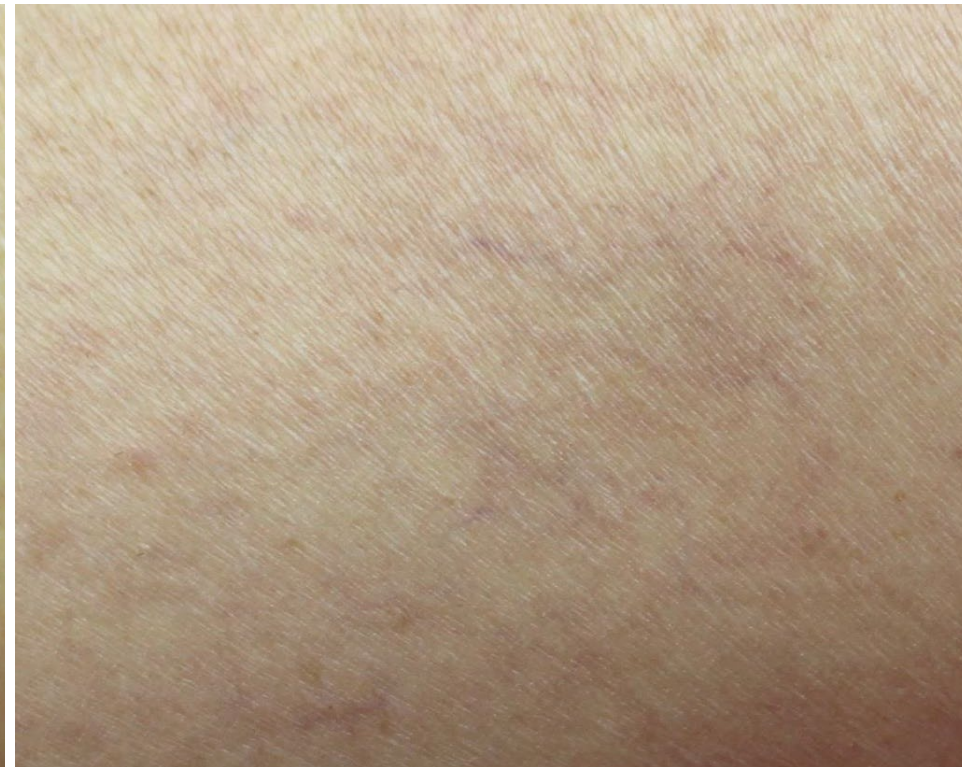

# Legs – Spider veins

|                               |  |
|-------------------------------|--|
| <b>Case Study – VNd#009-B</b> | <b>Dr. Cruzy Tagger, Viora Ltd.</b>  |
| Patient                       | Female, 44 years old   |
| Number of Treatments          | <b>2 V-Nd:YAG</b> (2 x 4 mm <sup>2</sup> spot size, 180-220 J/cm <sup>2</sup> , 15 ms, Single) |



Before



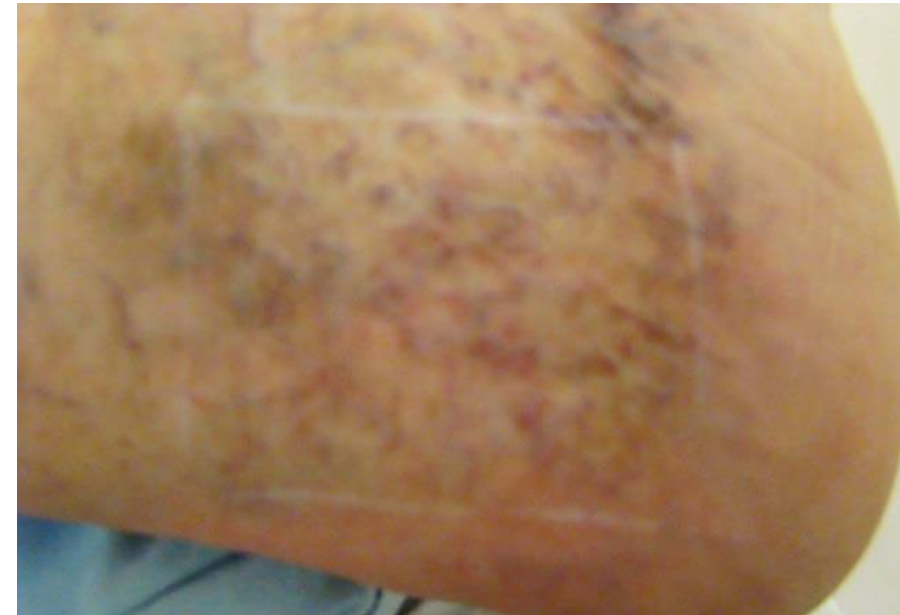
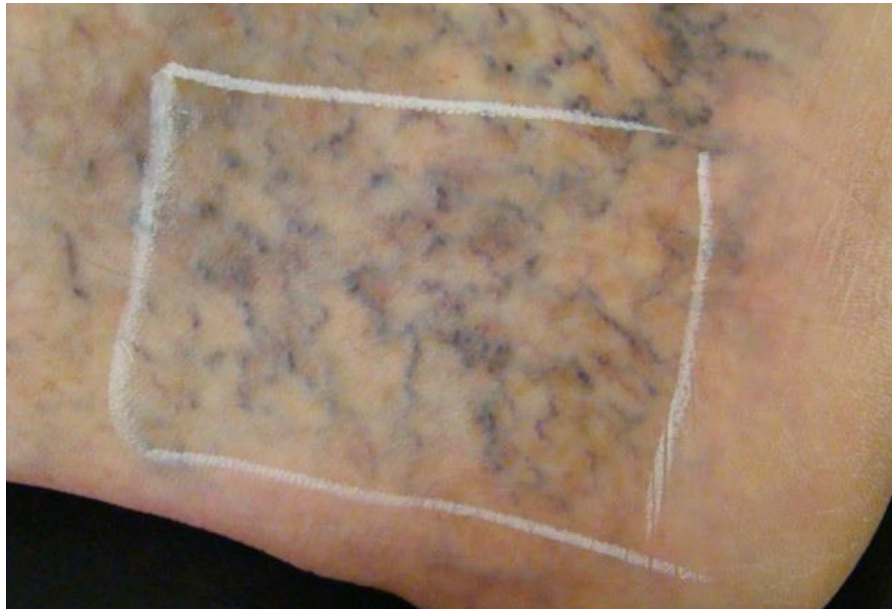
After





# Spider veins

|                             |                                      |
|-----------------------------|--------------------------------------|
| <b>Case Study – VNd#032</b> | <b>Dr. Tzachi Shelkovitz, Israel</b> |
| Patient                     | Male, 55 years old                   |
| Number of Treatments        | <b>1 V-Nd:YAG</b> (3.5 mm spot size) |



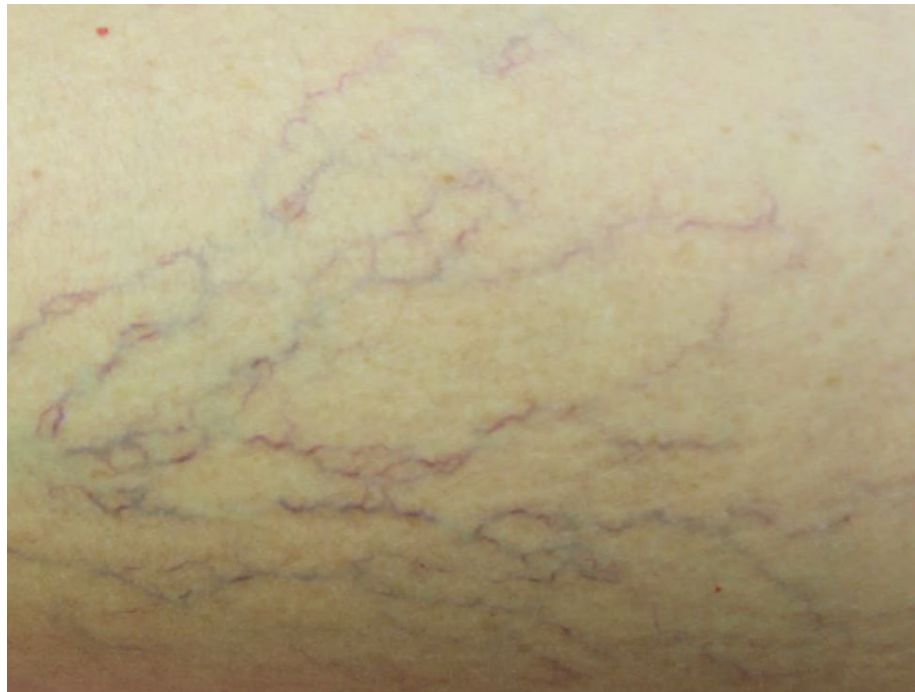Before

After

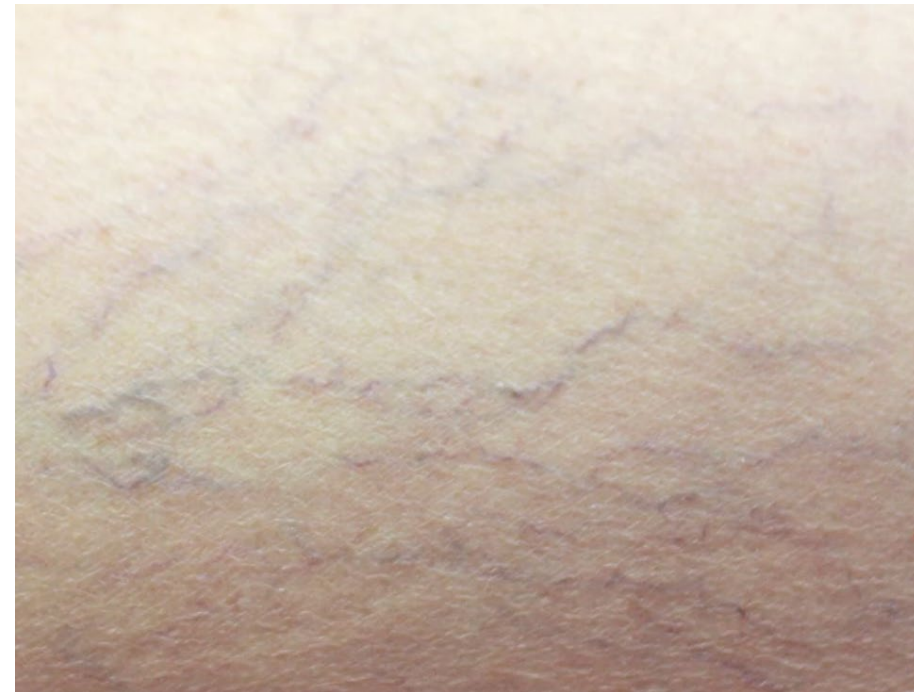

# Legs – Spider veins

|                               |   |
|-------------------------------|---|
| <b>Case Study – VNd#009-C</b> | <b>Dr. Cruzy Tagger, Viora Ltd.</b>   |
| Patient                       | Female, 44 years old  |
| Number of Treatments          | <b>1 V-Nd:YAG</b> (3.5 mm spot, 150-180 J/cm <sup>2</sup> , 15-20 ms. Single) |



Before

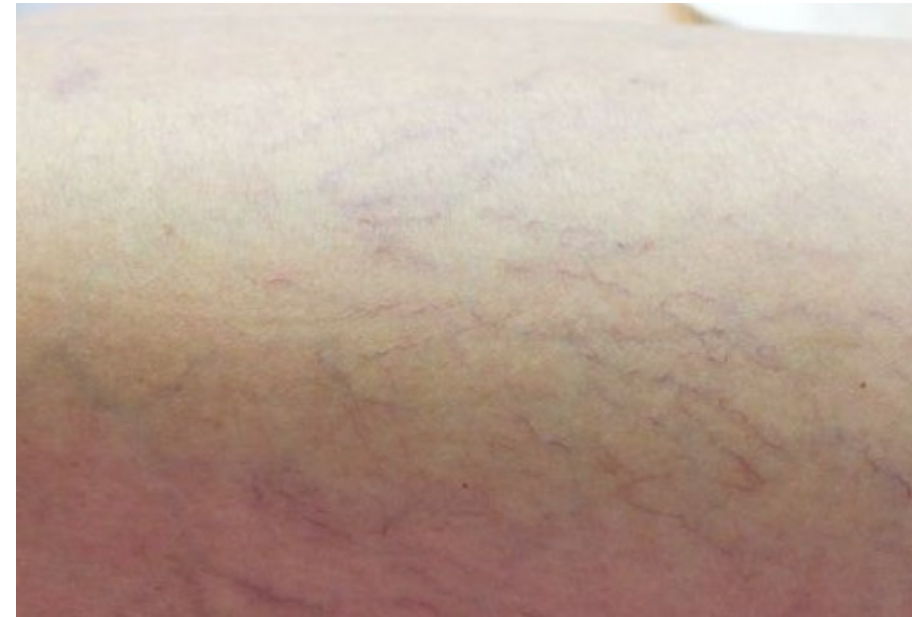
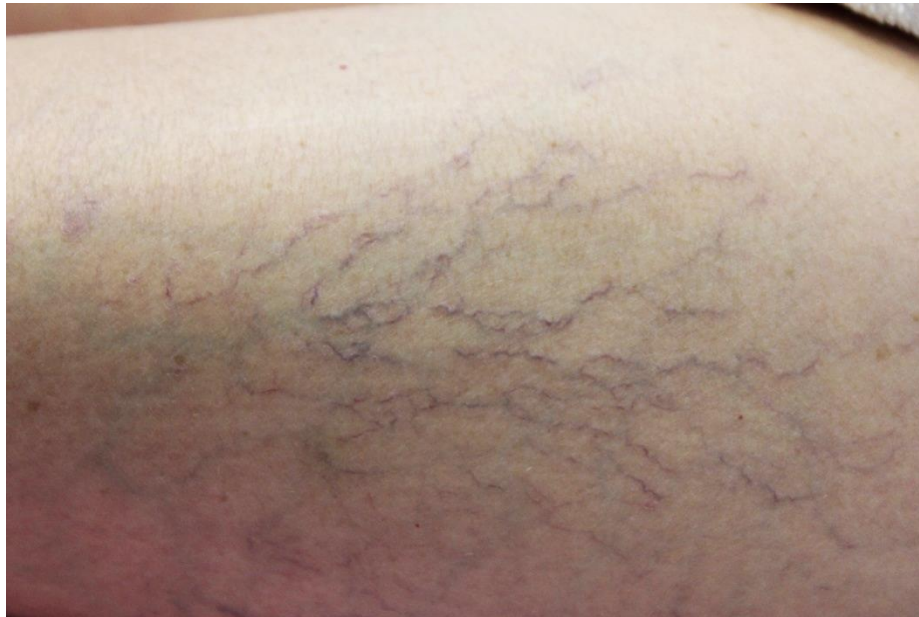
After



# Legs – Spider veins

|                               |                                      |
|-------------------------------|--------------------------------------|
| <b>Case Study – VNd#009-D</b> | <b>Dr. Cruzy Tagger, Viora Ltd.</b>  |
| Patient                       | Female, 44 years old                 |
| Number of Treatments          | <b>1 V-Nd:YAG</b> (3.5 mm spot size) |



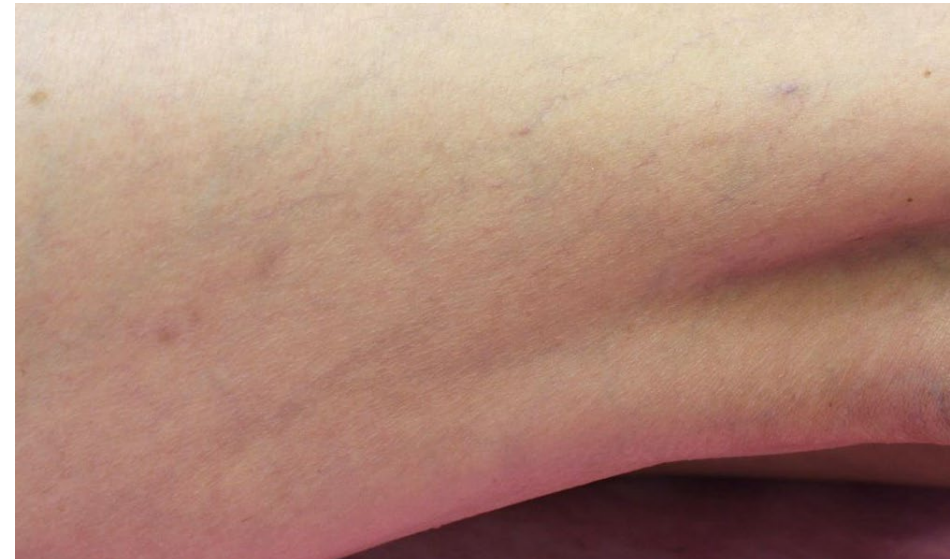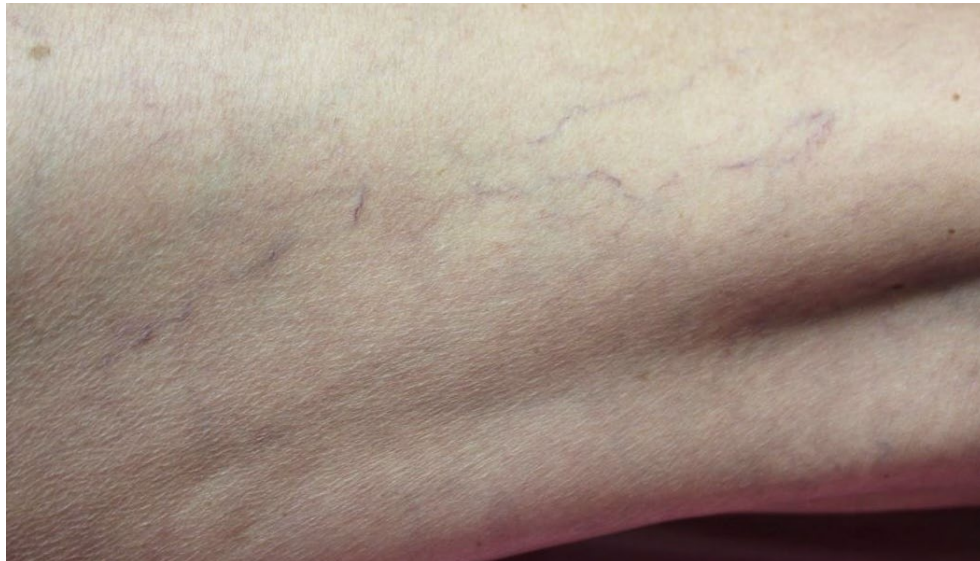Before

After



# Legs – Spider veins

|                               |                                      |
|-------------------------------|--------------------------------------|
| <b>Case Study – VNd#009-E</b> | <b>Dr. Cruzy Tagger, Viora Ltd.</b>  |
| Patient                       | Female, 44 years old                 |
| Number of Treatments          | <b>1 V-Nd:YAG</b> (3.5 mm spot size) |



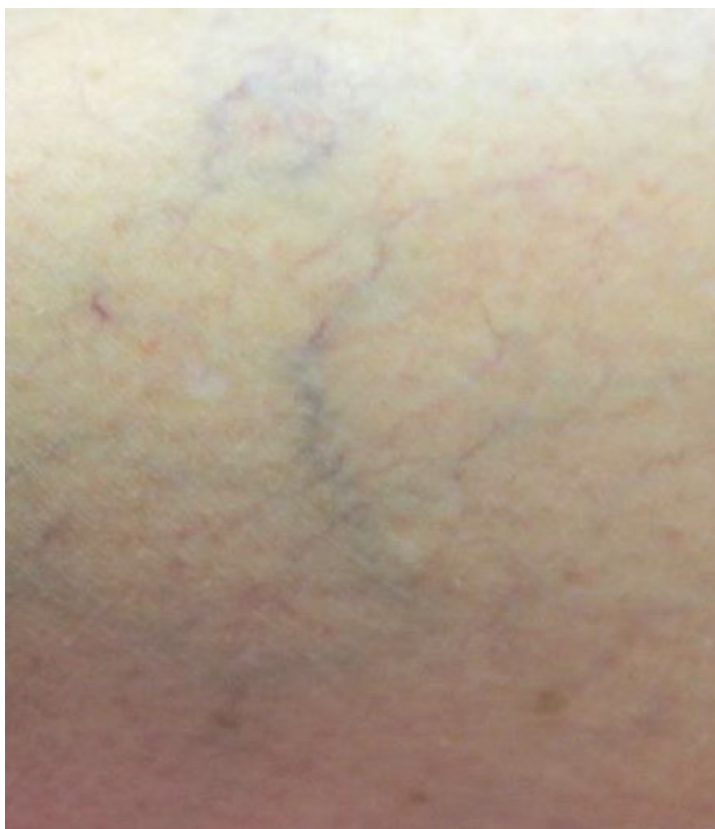Before

After

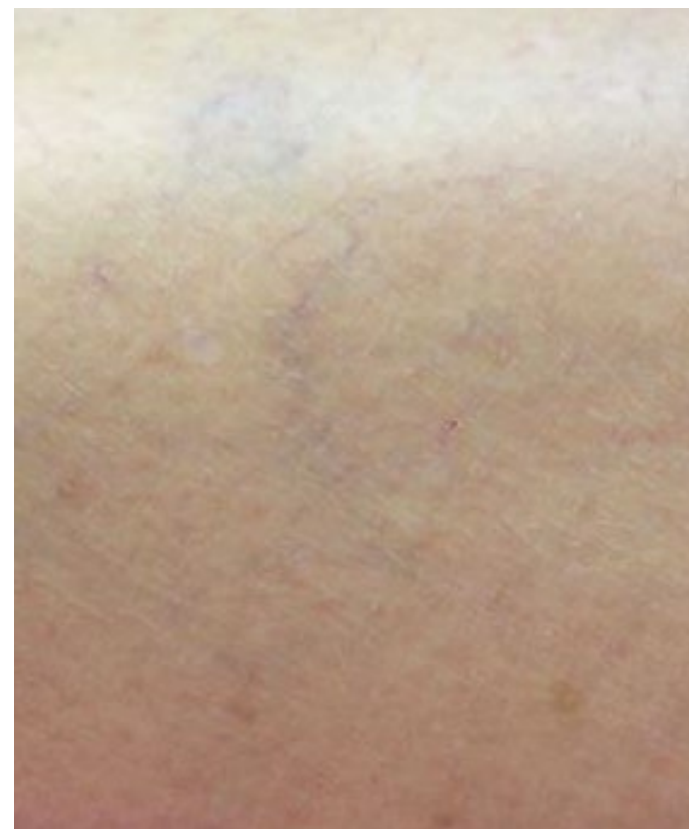

# Legs veins

|                               |   |
|-------------------------------|---|
| <b>Case Study – VNd#009-F</b> | <b>Dr. Cruzy Tagger, Viora Ltd.</b>   |
| Patient                       | Female, 44 years old  |
| Number of Treatments          | <b>1 V-Nd:YAG</b> (5.5 mm spot size, 130 J/cm <sup>2</sup> , 25 ms, Single) |



Before

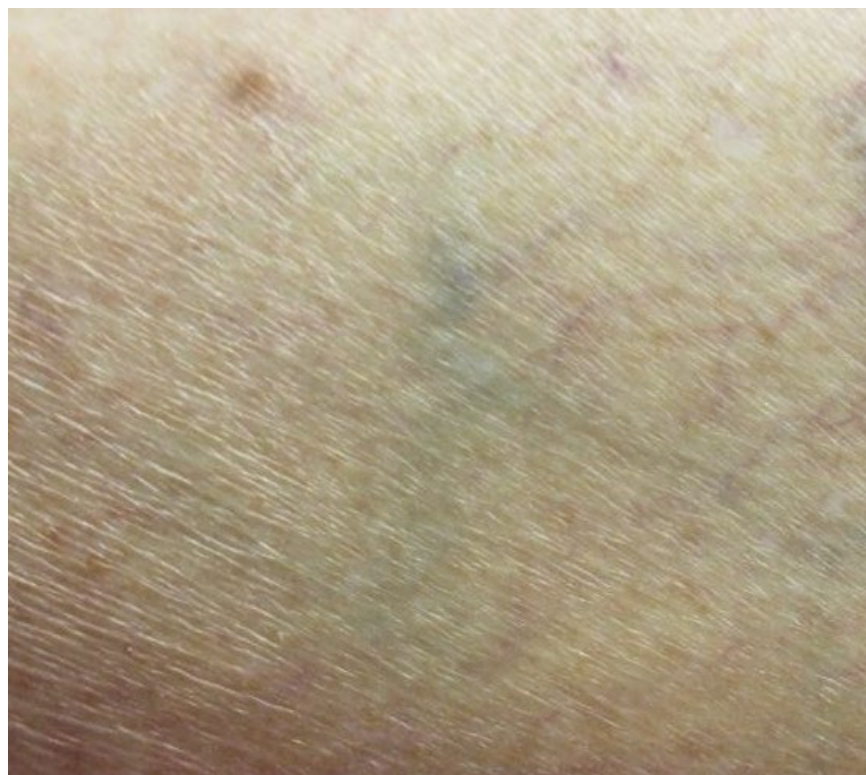

2 months after

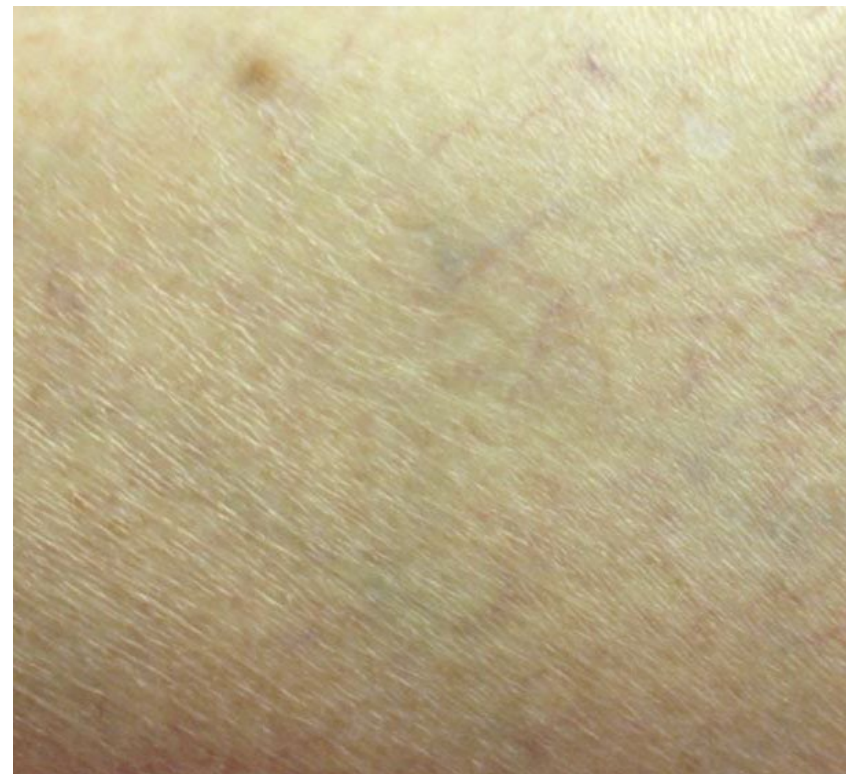

# Legs veins

|                               |                                      |
|-------------------------------|--------------------------------------|
| <b>Case Study – VNd#009-G</b> | <b>Dr. Cruzy Tagger, Viora Ltd.</b>  |
| Patient                       | Female, 44 years old                 |
| Number of Treatments          | <b>1 V-Nd:YAG</b> (5.5 mm spot size) |



Before

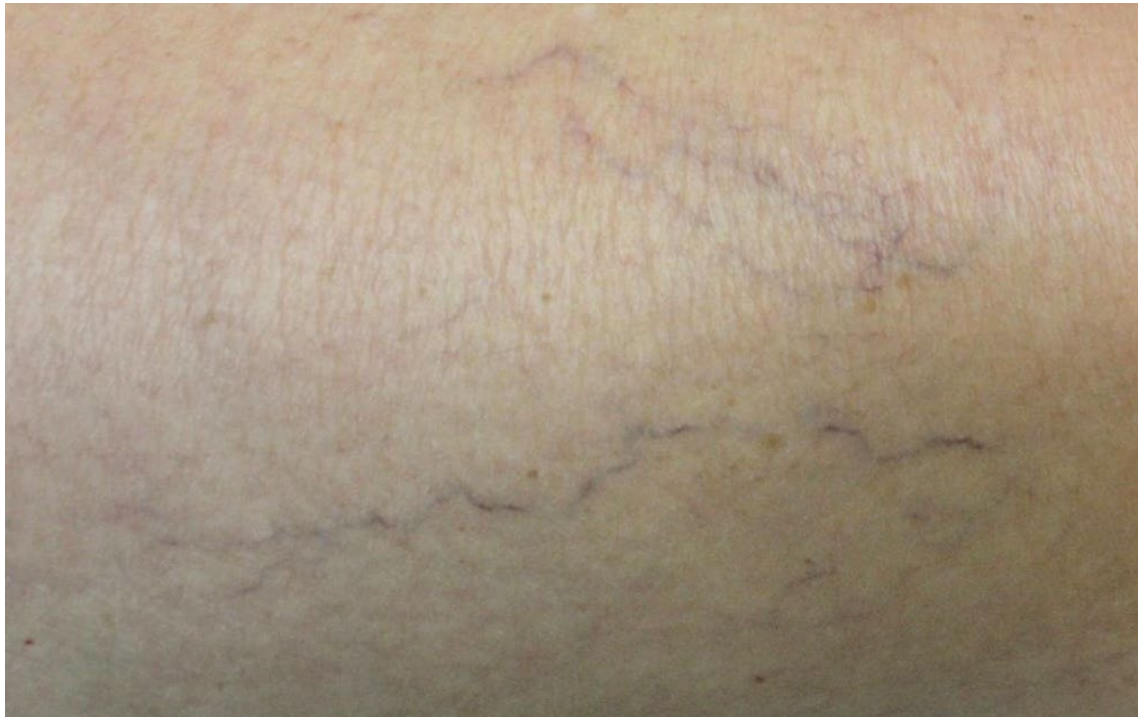

Immediately after

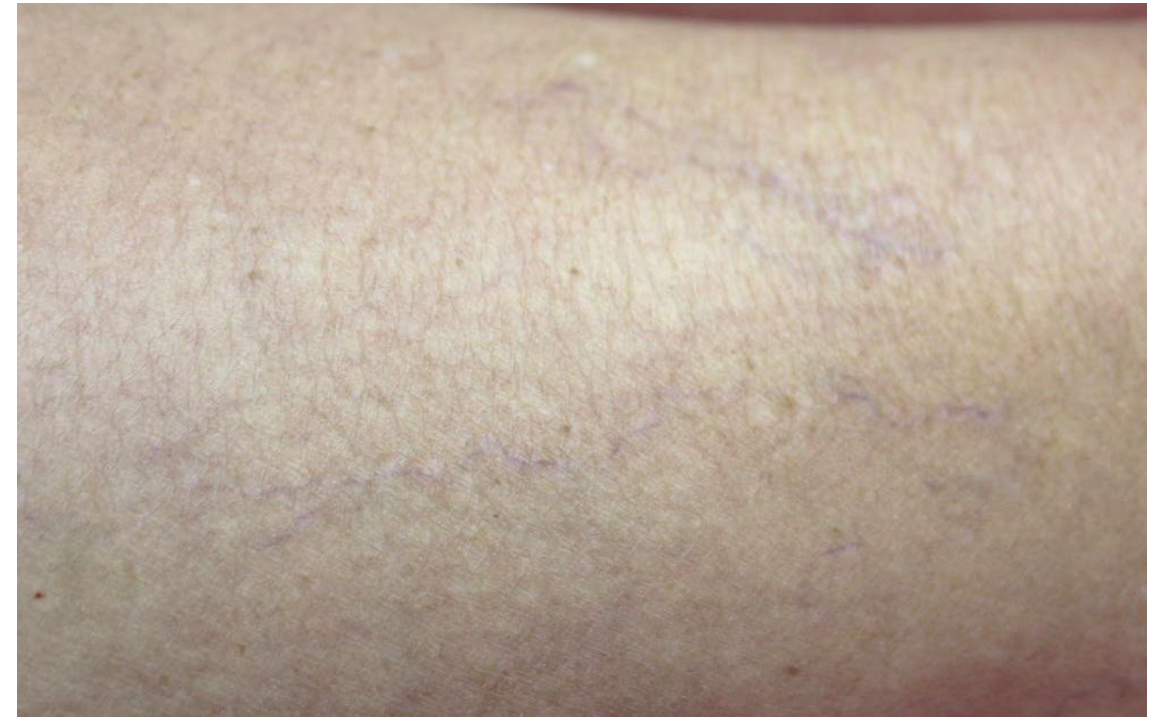

# Telangiectasia

|                               |   |
|-------------------------------|---|
| <b>Case Study – VNd#009-H</b> | <b>Dr. Cruzy Tagger, Viora Ltd.</b>                 |
| Patient                       | Female, 44 years old                                |
| Number of Treatments          | <b>1 V-Nd:YAG</b> (2 x 4 mm <sup>2</sup> spot size) |



Before

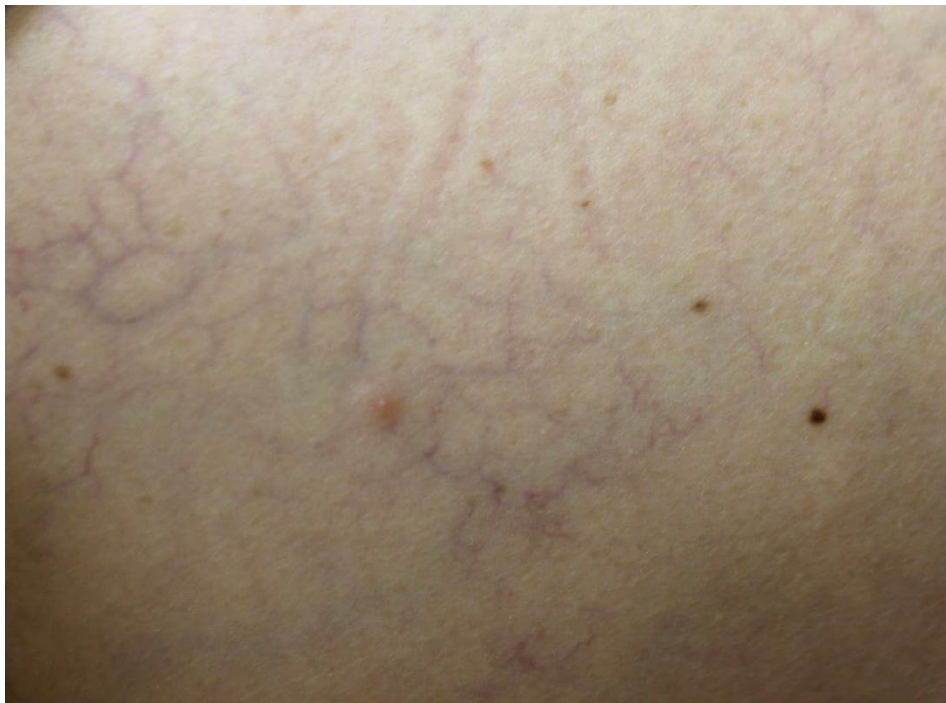

1 week after

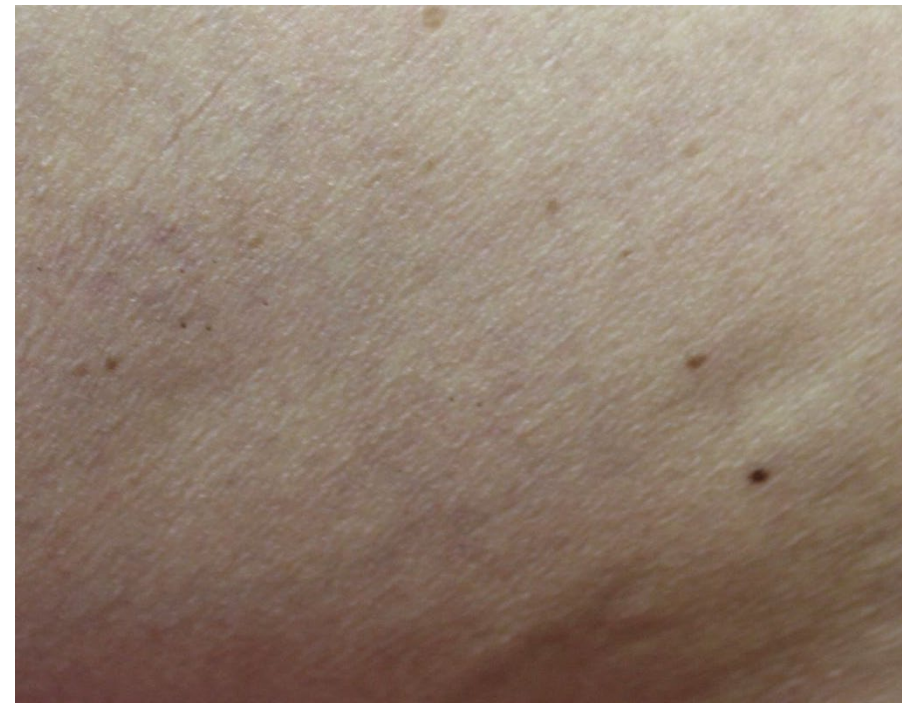

# Legs – Spider veins

|                             |   |
|-----------------------------|---|
| <b>Case Study – VNd#011</b> | <b>Dr. Cruzy Tagger, Viora Ltd.</b>                 |
| Patient                     | Female, XX years old                                |
| Number of Treatments        | <b>1 V-Nd:YAG</b> (2 x 4 mm <sup>2</sup> spot size) |



Before



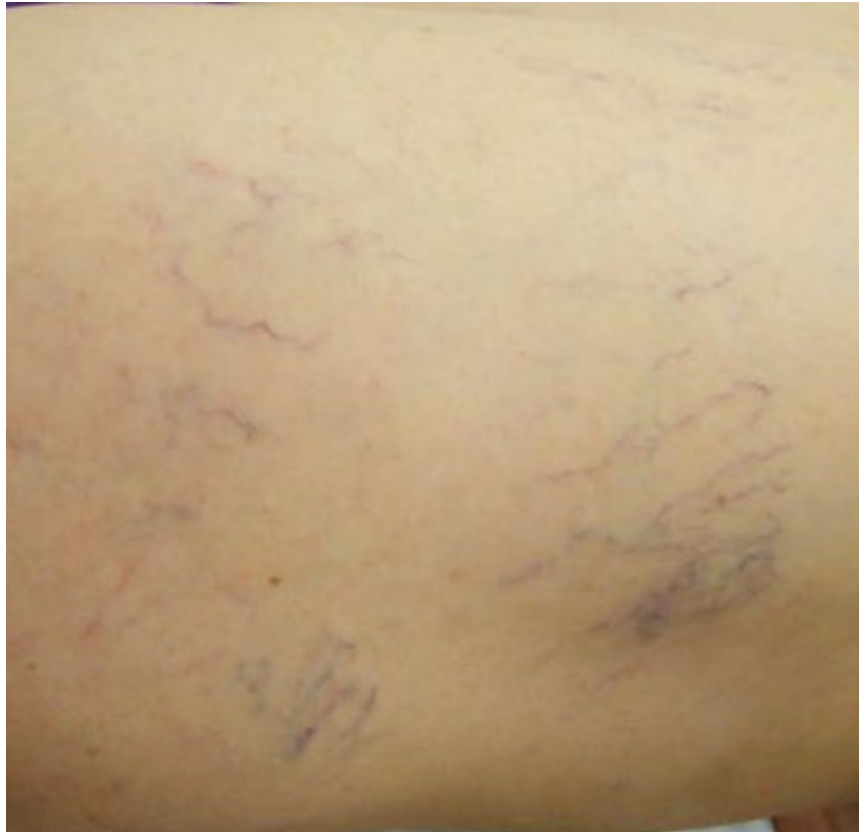After



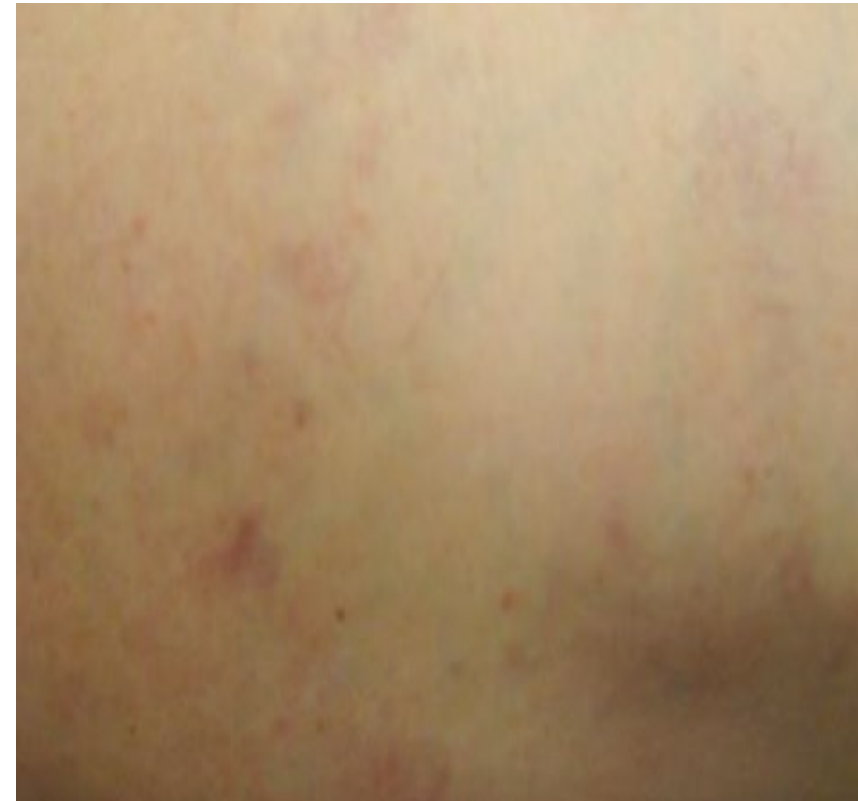

# Telangiectasia

|                               |  |
|-------------------------------|--|
| <b>Case Study – VNd#026-A</b> | <b>Dr. Tzachi Shelkovitz, Israel</b>                           |
| Patient                       | Female, 56 years old   |
| Number of Treatments          | <b>3 V-Nd:YAG</b> (5.5 mm and 2 x 4 mm <sup>2</sup> spot size) |



Before

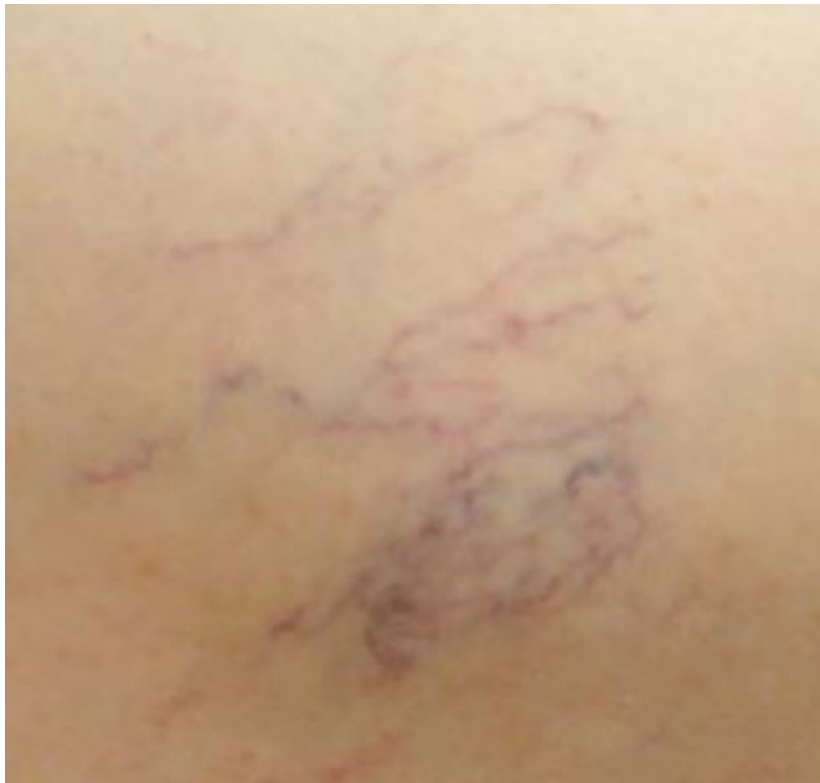

4 weeks after 3 treatments

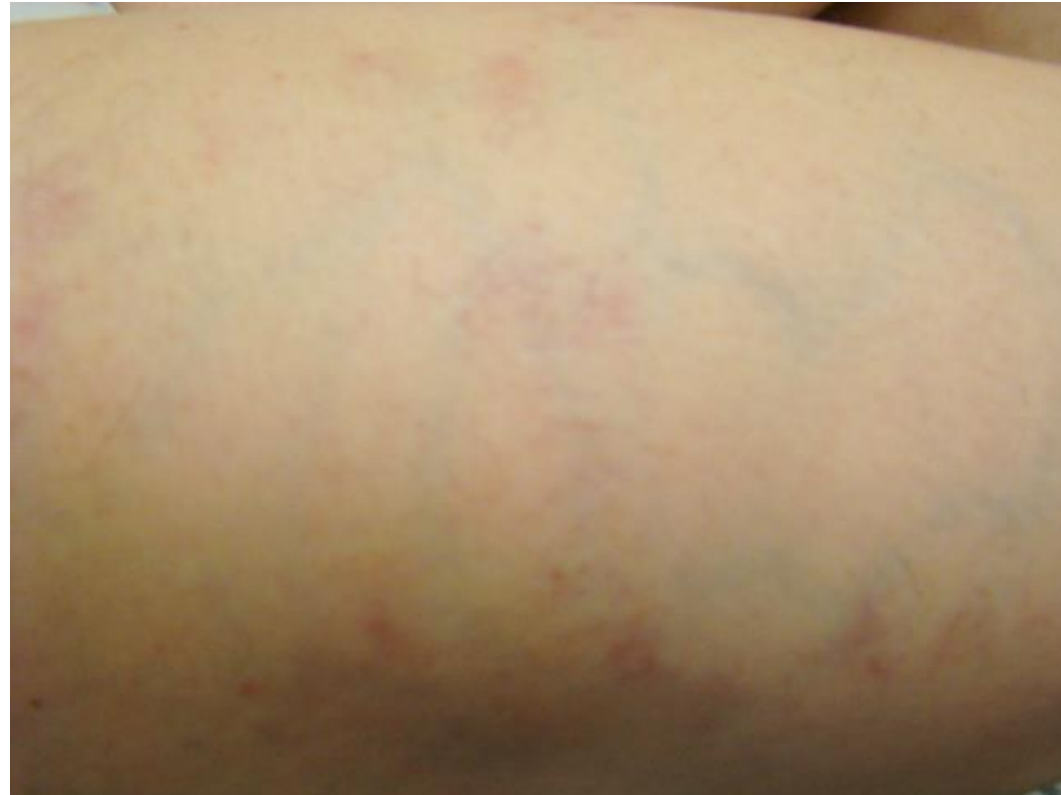

# Telangiectasia

|                               |  |
|-------------------------------|--|
| <b>Case Study – VNd#026-B</b> | <b>Dr. Tzachi Shelkovitz, Israel</b>                           |
| Patient                       | Female, 56 years old   |
| Number of Treatments          | <b>3 V-Nd:YAG</b> (5.5 mm and 2 x 4 mm <sup>2</sup> spot size) |



Before

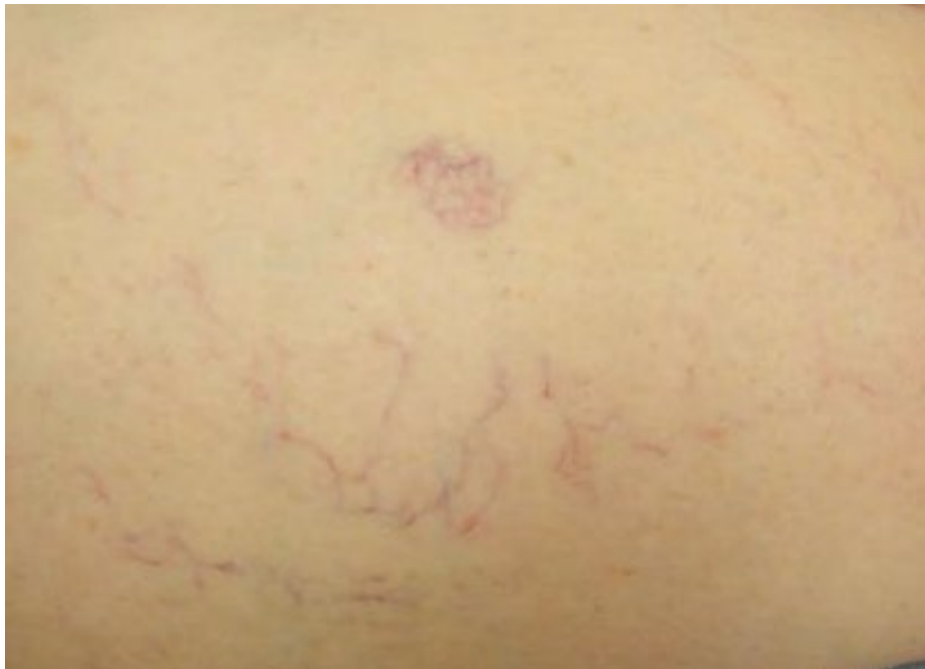

4 weeks after 3 treatments

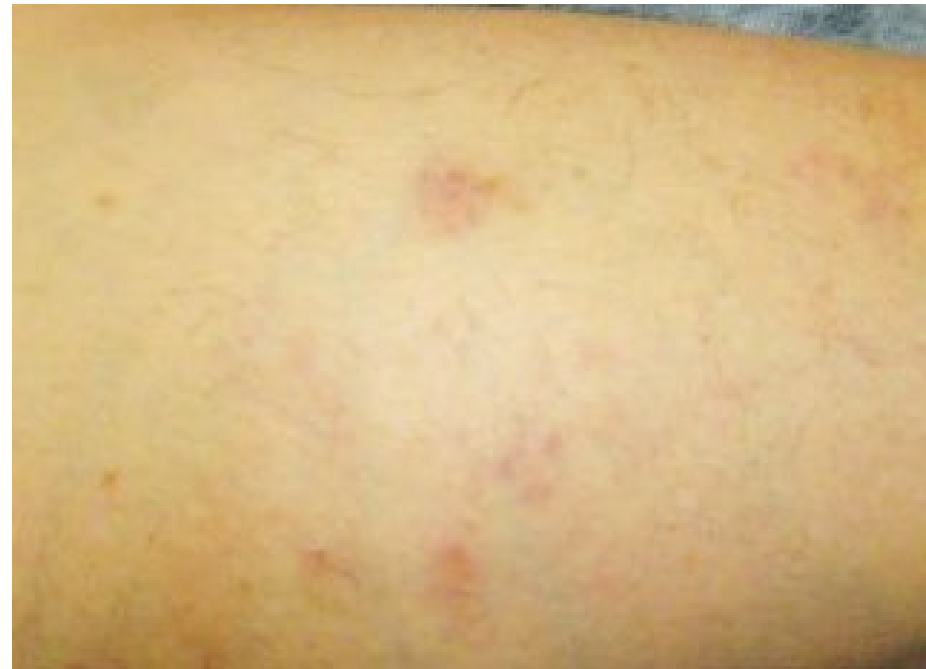

# Telangiectasia

|                               |  |
|-------------------------------|--|
| <b>Case Study – VNd#026-C</b> | <b>Dr. Tzachi Shelkovitz, Israel</b>                           |
| Patient                       | Female, 56 years old   |
| Number of Treatments          | <b>3 V-Nd:YAG</b> (5.5 mm and 2 x 4 mm <sup>2</sup> spot size) |



Before

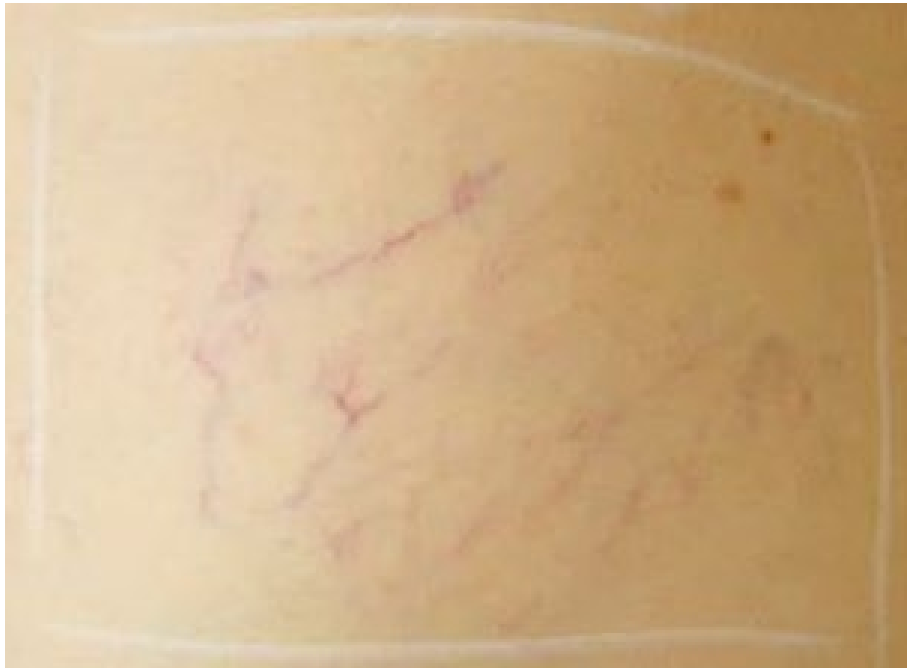


4 weeks after 3 treatments

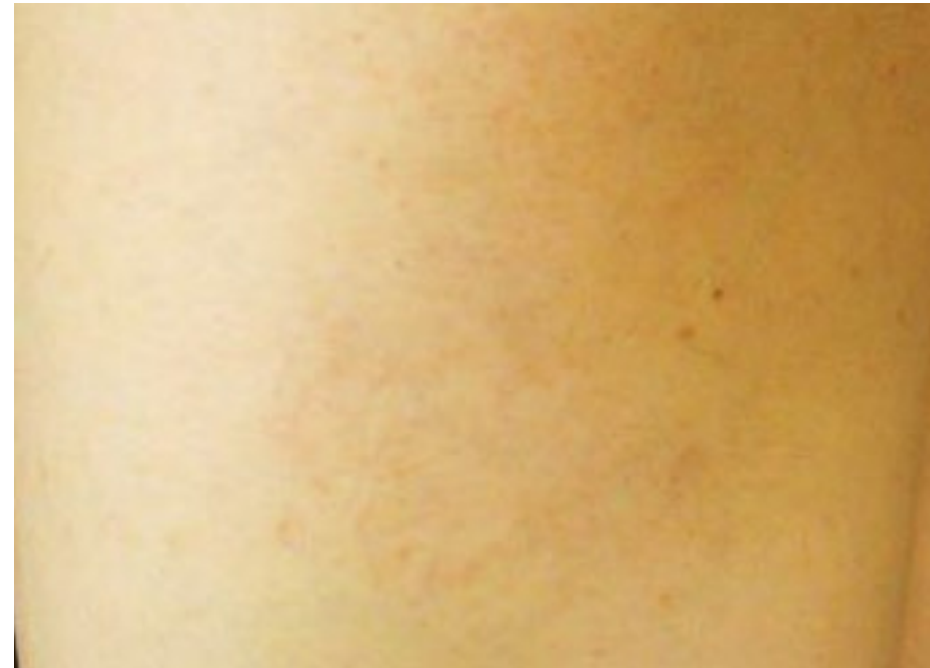

# Telangiectasia

|                               |  |
|-------------------------------|--|
| <b>Case Study – VNd#026-D</b> | <b>Dr. Tzachi Shelkovitz, Israel</b>                           |
| Patient                       | Female, 56 years old   |
| Number of Treatments          | <b>2 V-Nd:YAG</b> (5.5 mm and 2 x 4 mm <sup>2</sup> spot size) |



Before

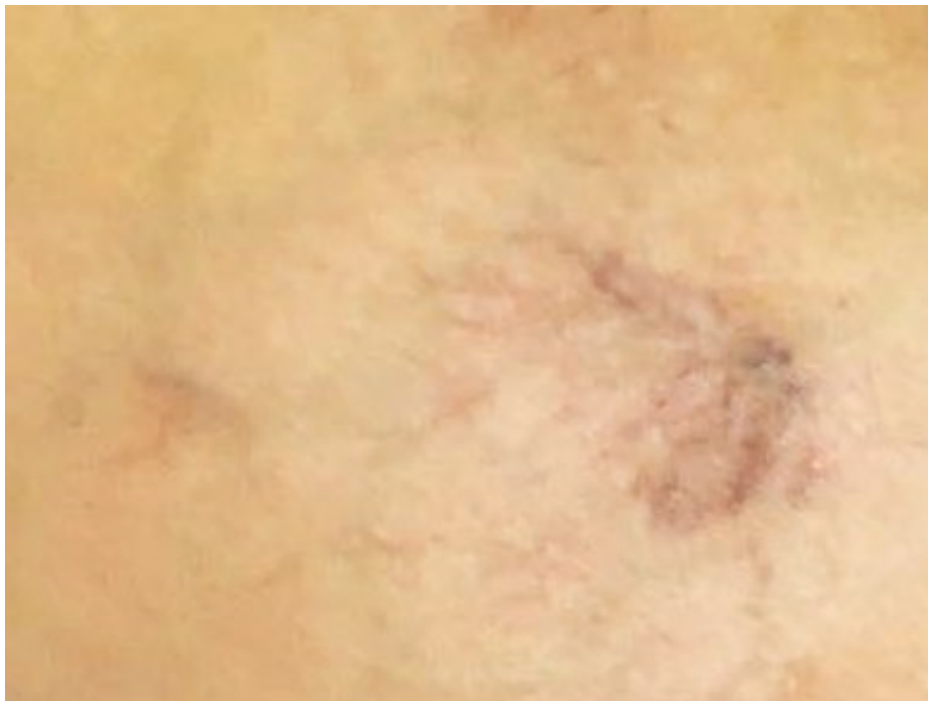

4 weeks after 2 treatments

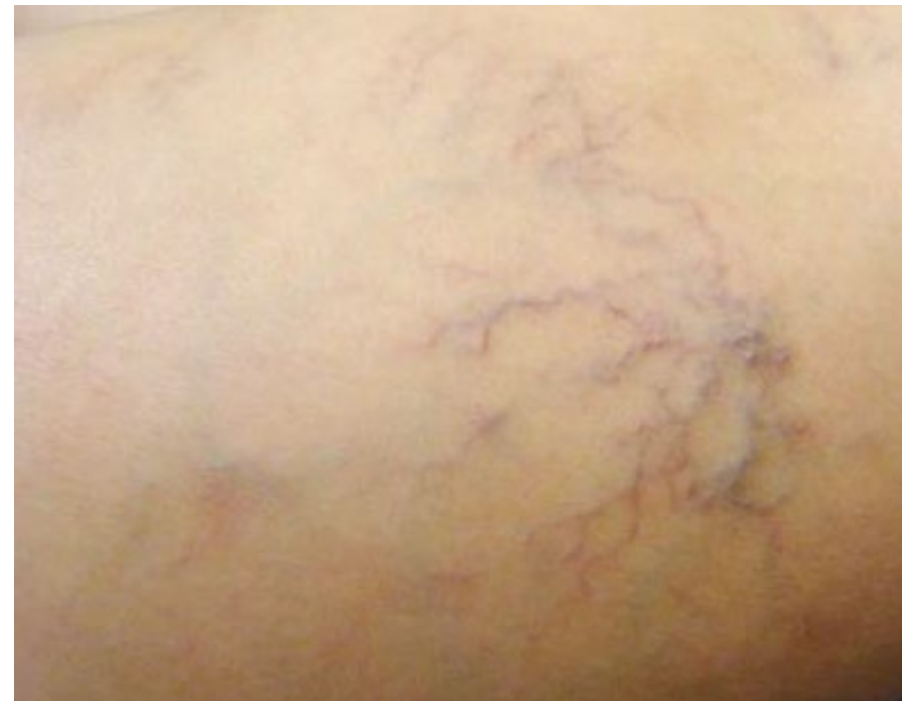

# Spider veins

|                             |                                      |
|-----------------------------|--------------------------------------|
| <b>Case Study – VNd#033</b> | <b>Dr. Tzachi Shelkovitz, Israel</b> |
| Patient                     | Female, 43 years old                 |
| Number of Treatments        | <b>1 V-Nd:YAG</b> (5.5 mm spot size) |



Before

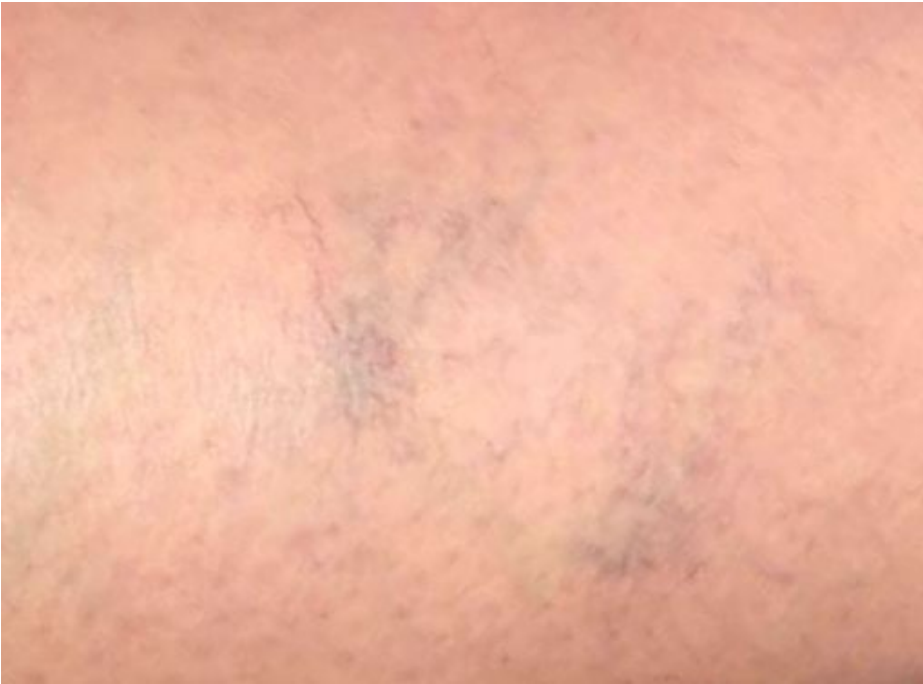
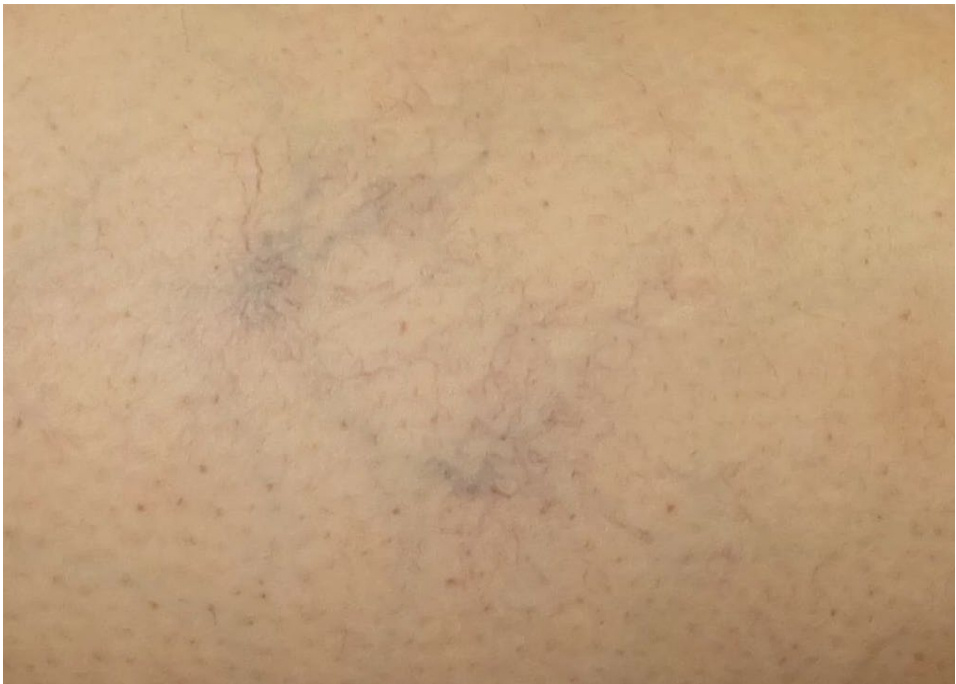
4 weeks after



# Spider veins

|                             |   |
|-----------------------------|---|
| <b>Case Study – VNd#034</b> | <b>Viora Ltd., China</b>                            |
| Patient                     | Female, 28 years old                                |
| Number of Treatments        | <b>2 V-Nd:YAG</b> (2 x 4 mm <sup>2</sup> spot size) |



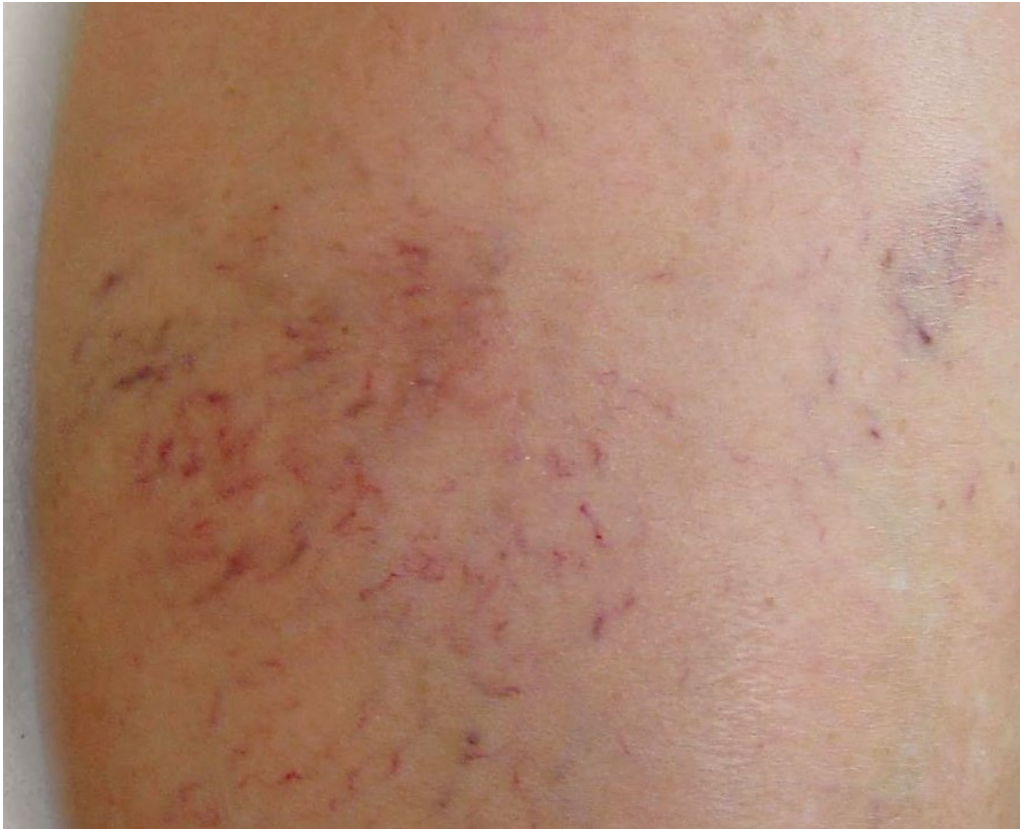Before

4 weeks after 3 treatments

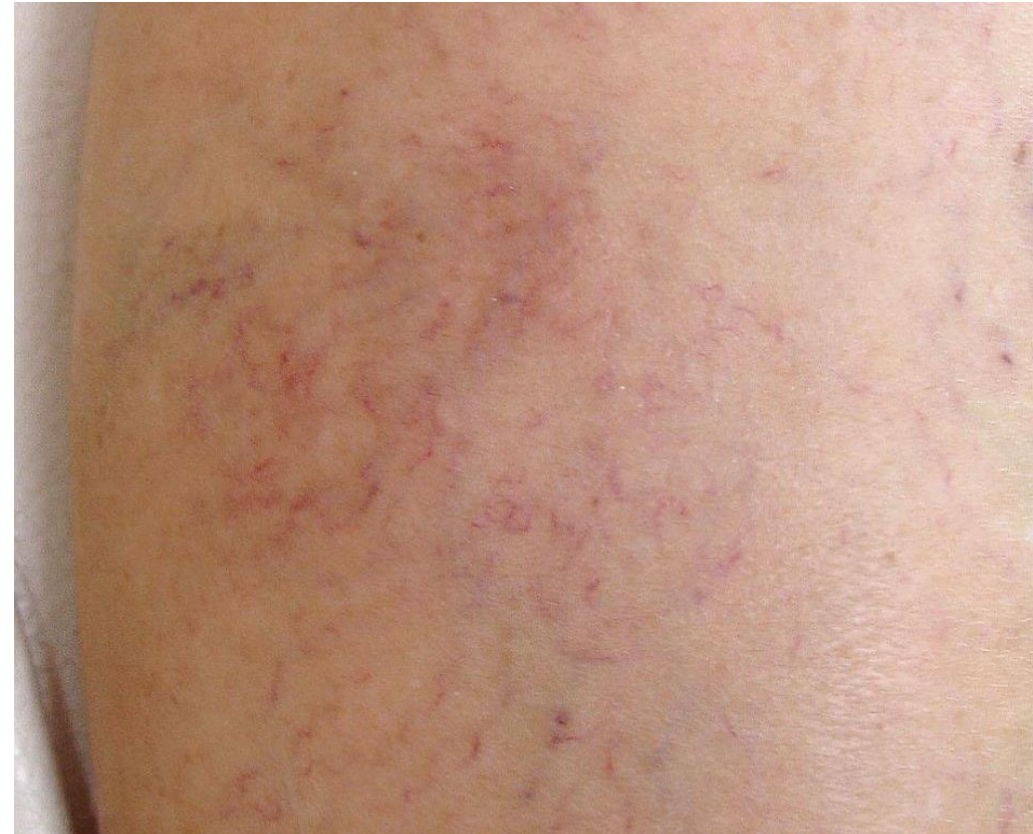

# Spider veins

|                             |   |
|-----------------------------|---|
| <b>Case Study – VNd#035</b> | <b>Viora Ltd., China</b>                            |
| Patient                     | Female, 36 years old                                |
| Number of Treatments        | <b>3 V-Nd:YAG</b> (2 x 4 mm <sup>2</sup> spot size) |



Before

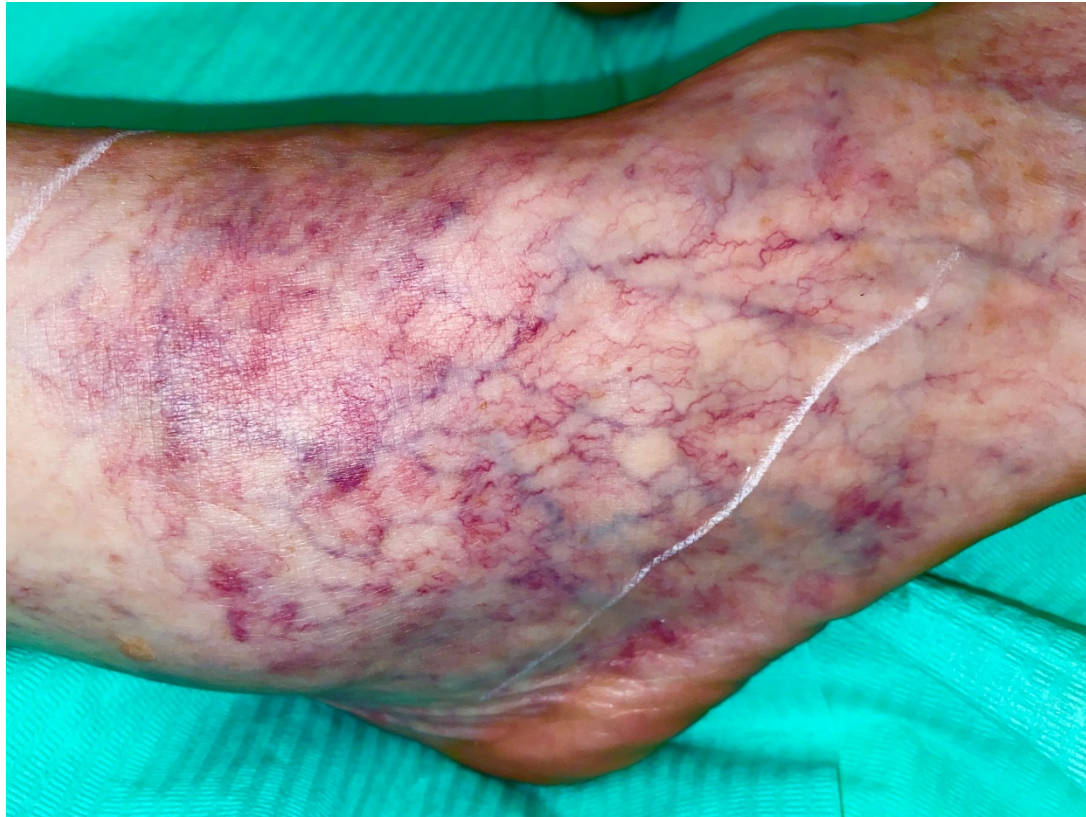

4 weeks after 3 treatments

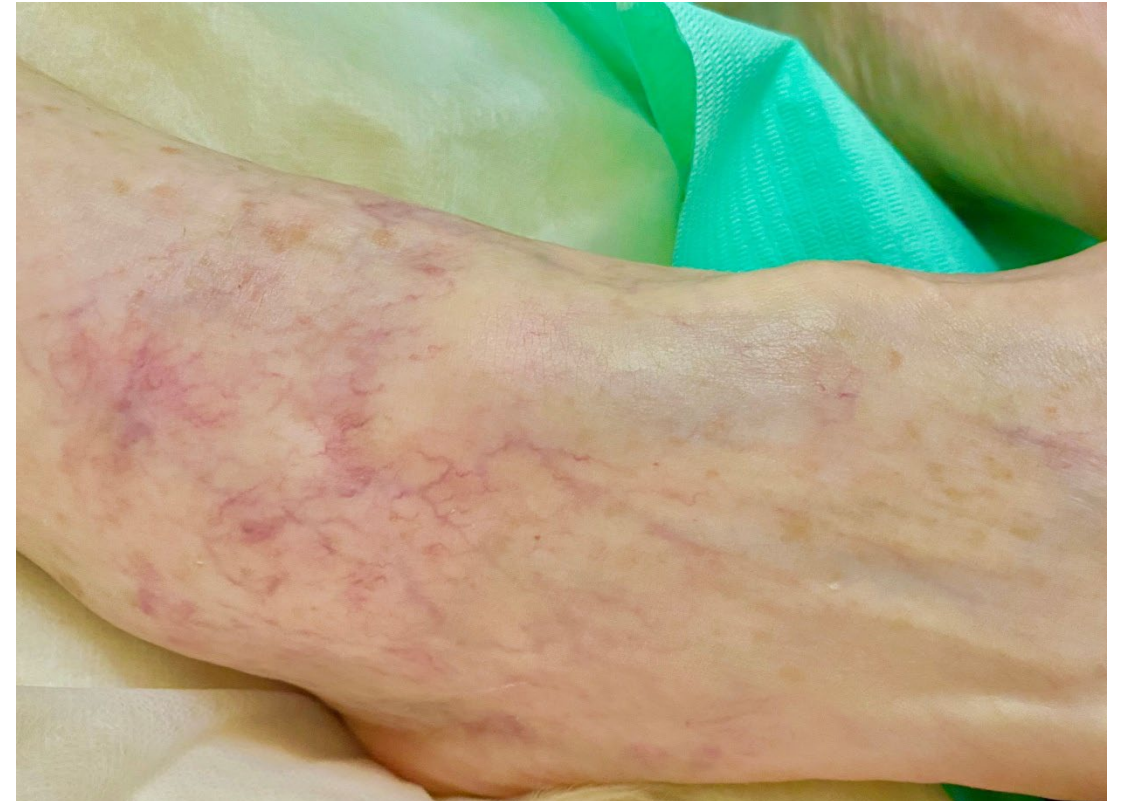


# Ankle Spider veins

|                             |   |
|-----------------------------|---|
| <b>Case Study – VNd#059</b> | <b>Dr. Lee Bottem, Broken Arrow, OK, USA</b>            |
| Patient                     | Female, 60 years old                                    |
| Number of Treatments        | <b>1 V-Nd:YAG (3.5 mm, 25 ms, 140 J/cm<sup>2</sup>)</b> |



Before



After



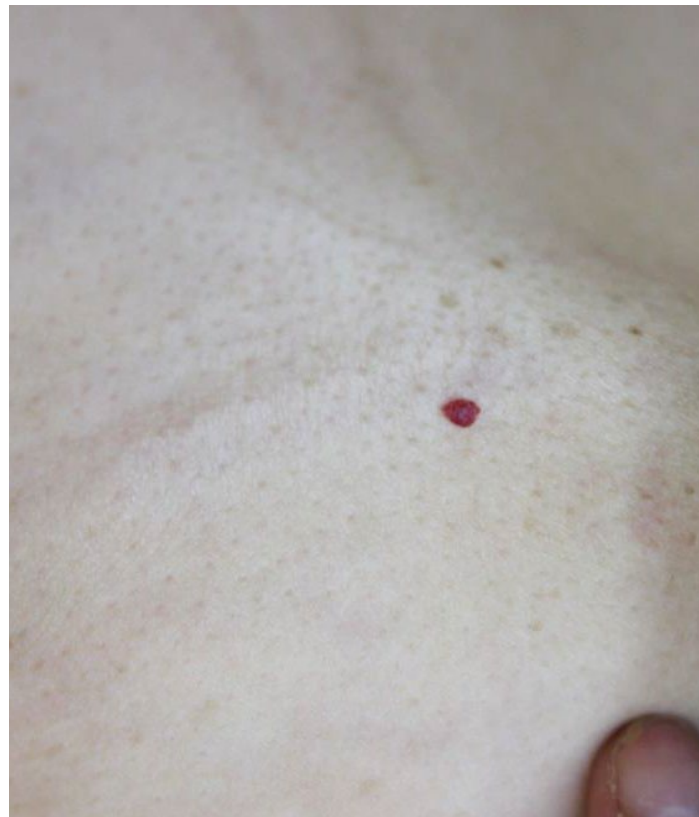

# Hemangioma

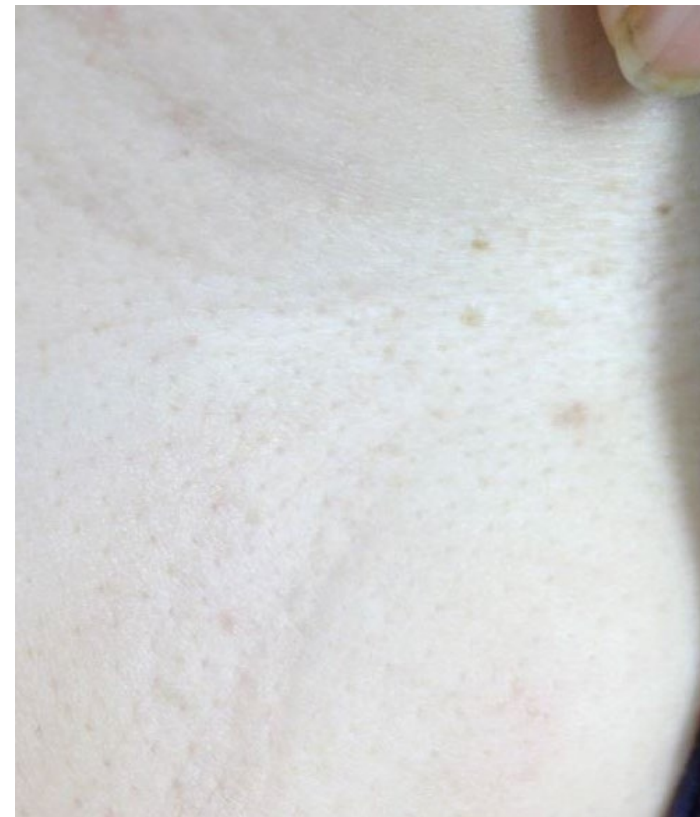


# Hemangioma

|                               |   |
|-------------------------------|---|
| <b>Case Study – VNd#008-B</b> | <b>Dr. Cruzy Tagger, Viora Ltd.</b>   |
| Patient                       | Female, 48 years old  |
| Number of Treatments          | <b>1 V-Nd:YAG</b> (3.5 mm spot size, 140 J/cm <sup>2</sup> , 20 ms, Single) |



Before

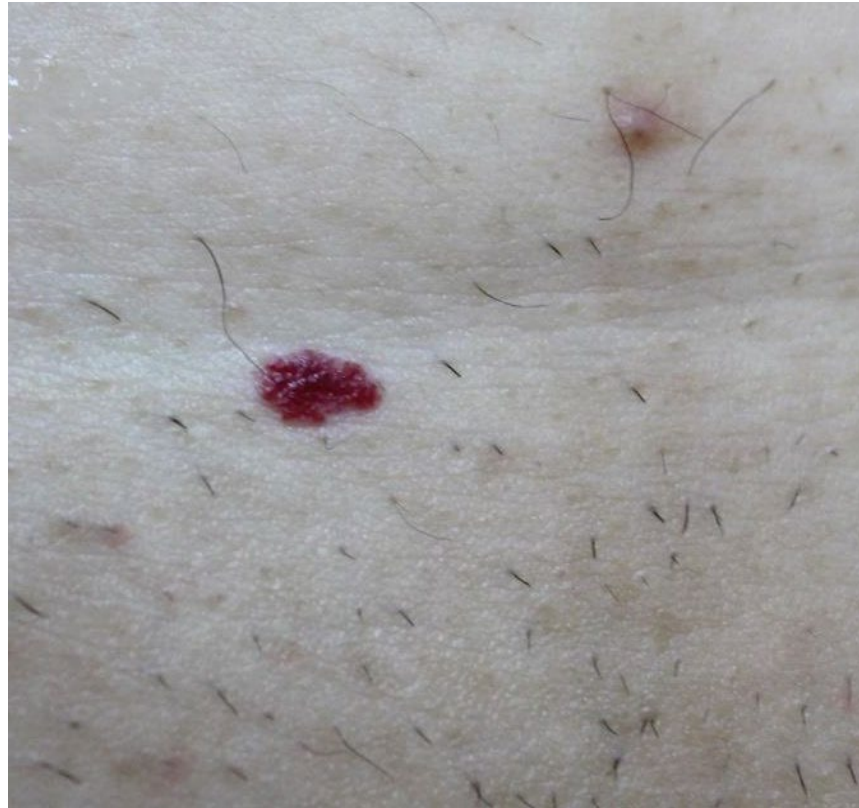

3 months after

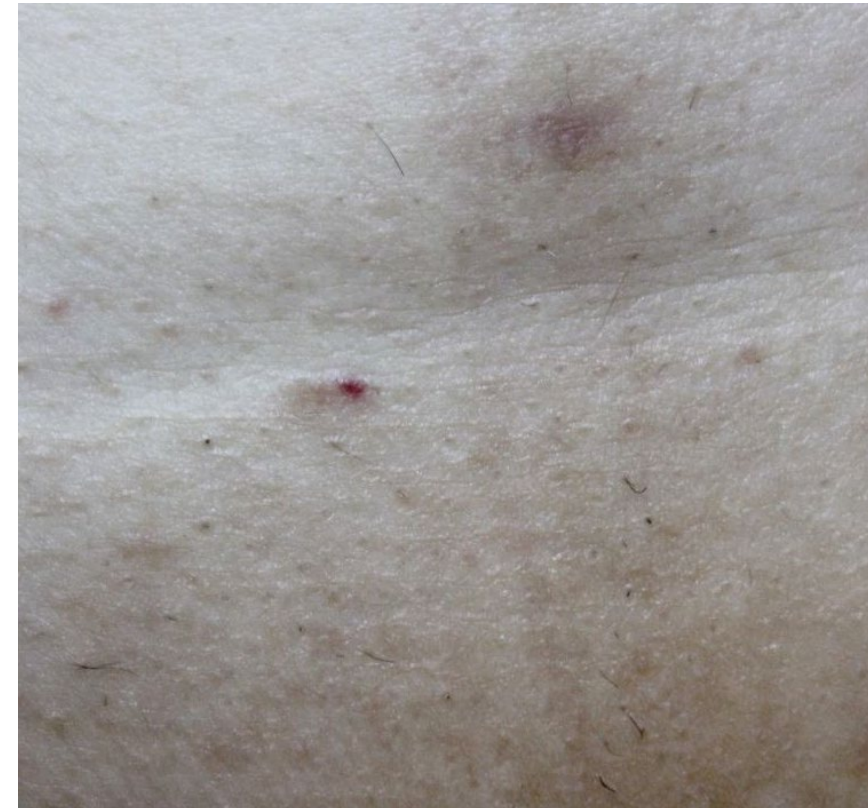

# Hemangioma

|                               |   |
|-------------------------------|---|
| <b>Case Study – VNd#008-A</b> | <b>Dr. Cruzy Tagger, Viora Ltd.</b>   |
| Patient                       | Female, 48 years old  |
| Number of Treatments          | <b>1 V-Nd:YAG</b> (5.5 mm spot size, 140 J/cm <sup>2</sup> , 20 ms, Single) |



Before



After



**PWS**

  
**VIORA**  
Shape the Future



# Port Wine Stain

**Case Study – VN#039**

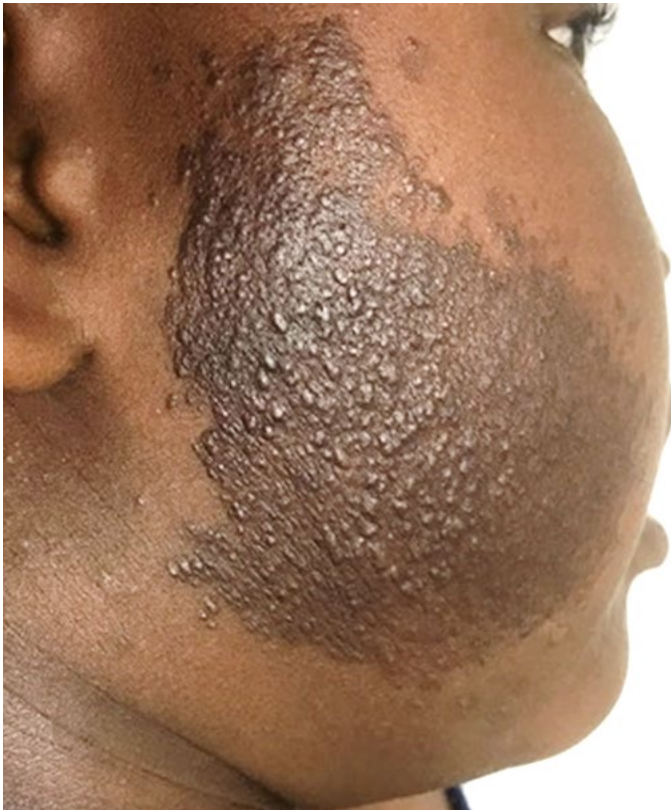**Dr. Matsidiso Moyaba , Polokwane, South Africa**

**Patient**

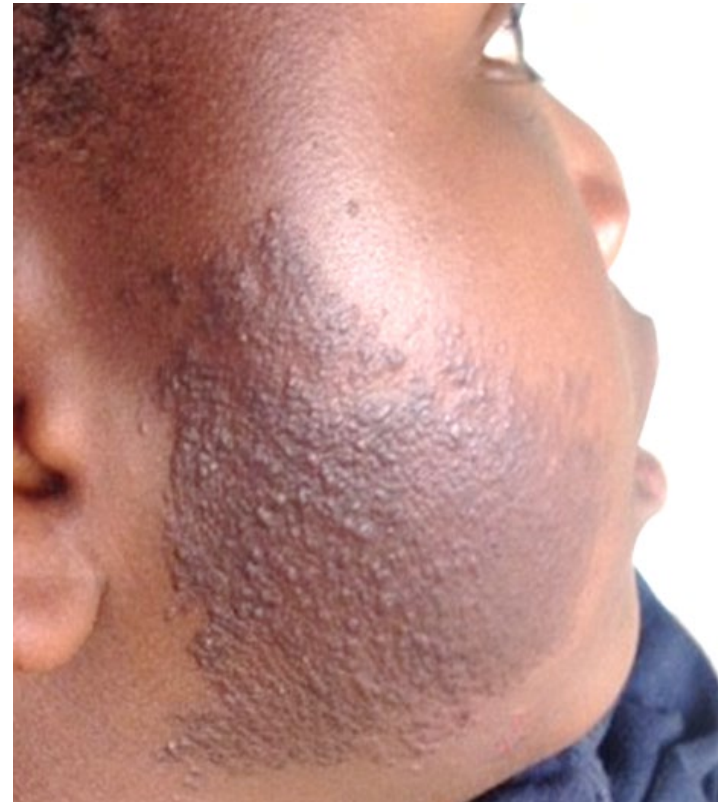Male, 26 years old (Fitzpatrick type V)

**Number of Treatments**

**5 V-Nd:YAG** (Single, 80 J/cm<sup>2</sup>, 5.5 mm spot size)



**Before**



**After**



# Face & Neck Port Wine Stain - Combination

**Case Study – CO#090**

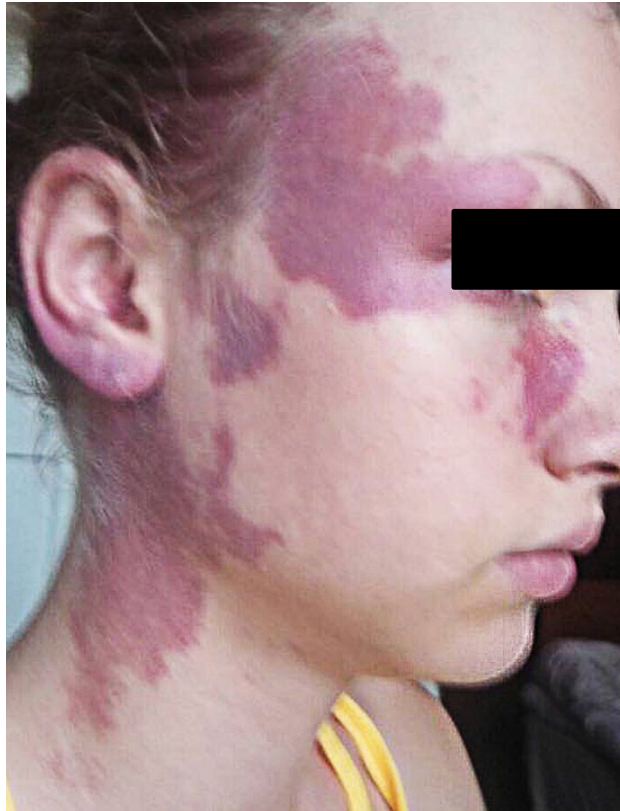**Dr. Anna Kudrina, Russia**

Patient

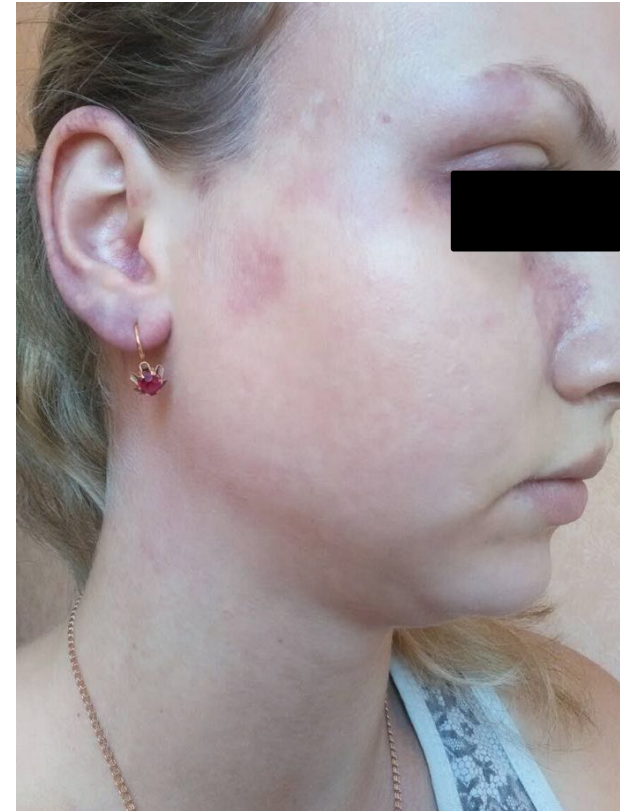Female

Number of Treatments

5 V-IPL – VP 530nm & V-Nd:YAG - 3.5 mm (around the eyes)



Before



After





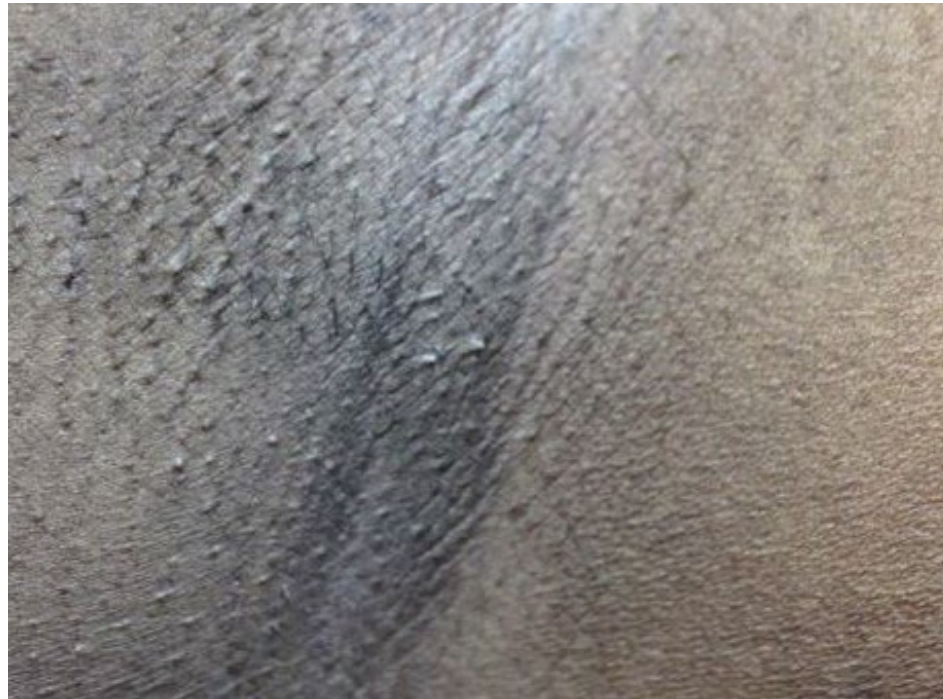# Hair Removal

  
**VIORA**  
Shape the Future

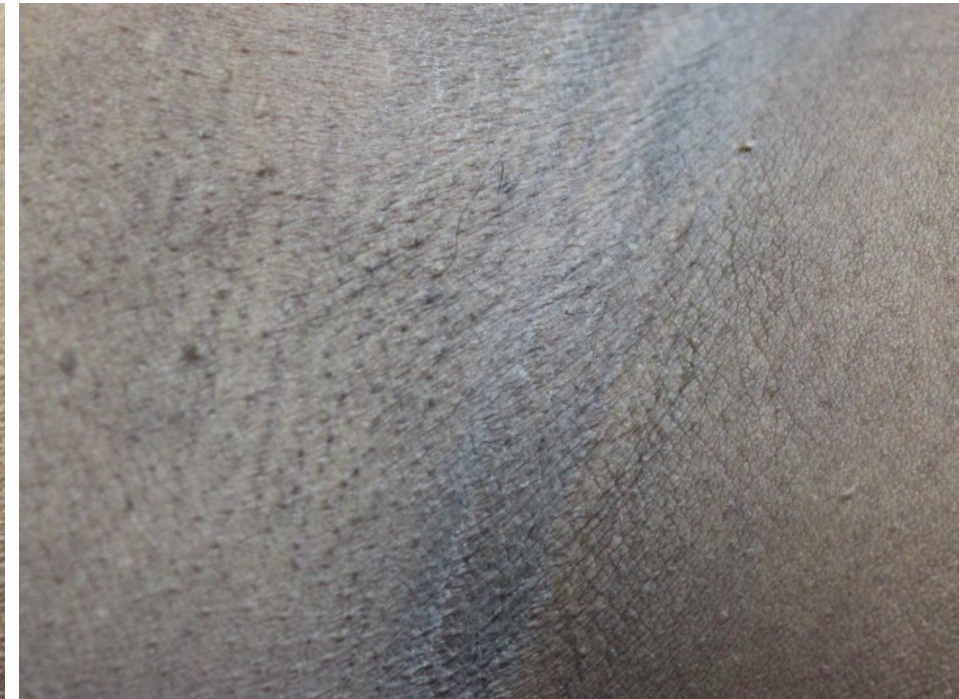

# Armpits Hair Removal

|                             |   |
|-----------------------------|---|
| <b>Case Study – VNd#012</b> | <b>Dr. Cruzy Tagger, Viora Ltd.</b>   |
| Patient                     | Female, 28 years old (Fitzpatrick VI)                                       |
| Number of Treatments        | <b>5 V-Nd:YAG</b> ( 9.5 mm spot size, 45 J/cm <sup>2</sup> , 25 ms, Single) |



Before



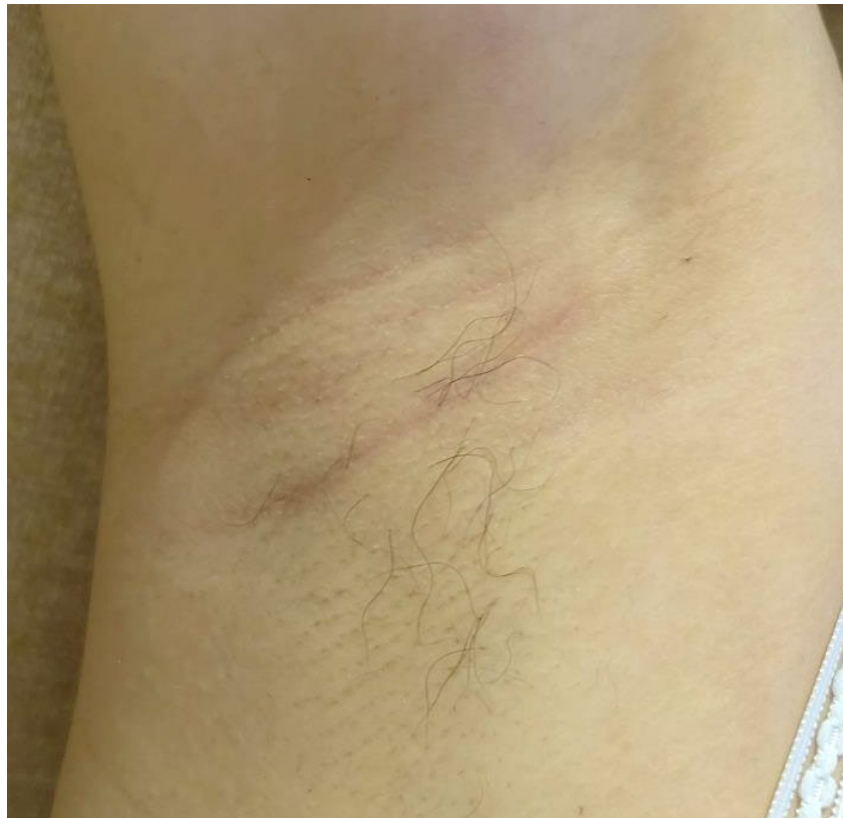After



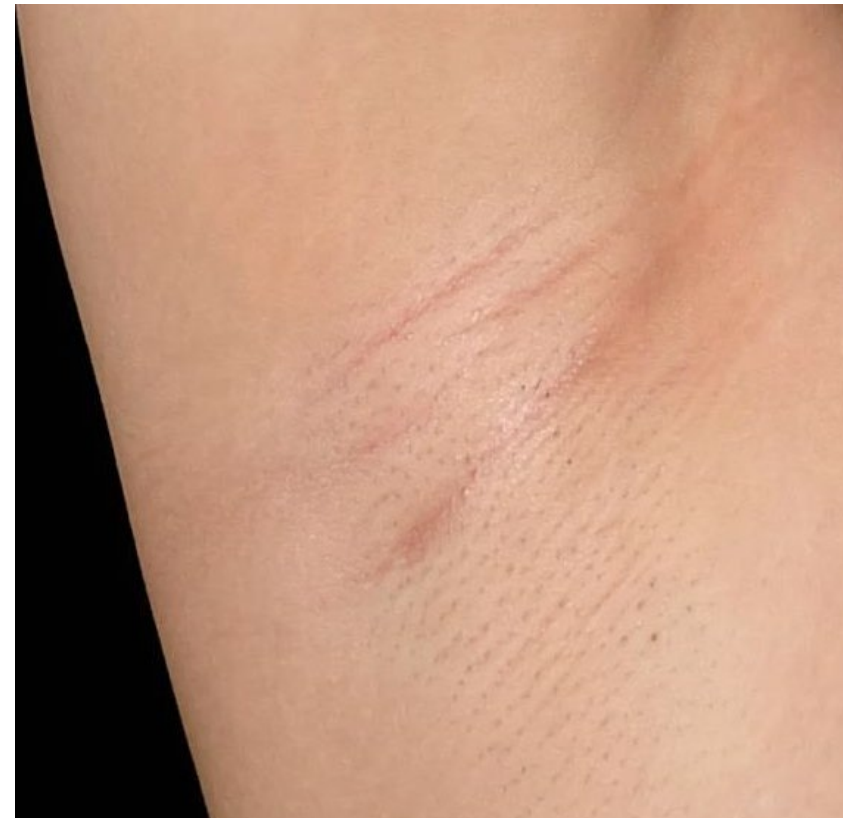

# Armpits Hair Removal

|                             |   |
|-----------------------------|---|
| <b>Case Study – VNd#036</b> | <b>Viora Ltd., China</b>                      |
| Patient                     | Female, 32 years old (Fitzpatrick IV)         |
| Number of Treatments        | <b>2 V-Nd:YAG</b> ( 9.5 mm spot size, Single) |



Before



After



# Facial Hair removal

**Case Study – VNd#038**

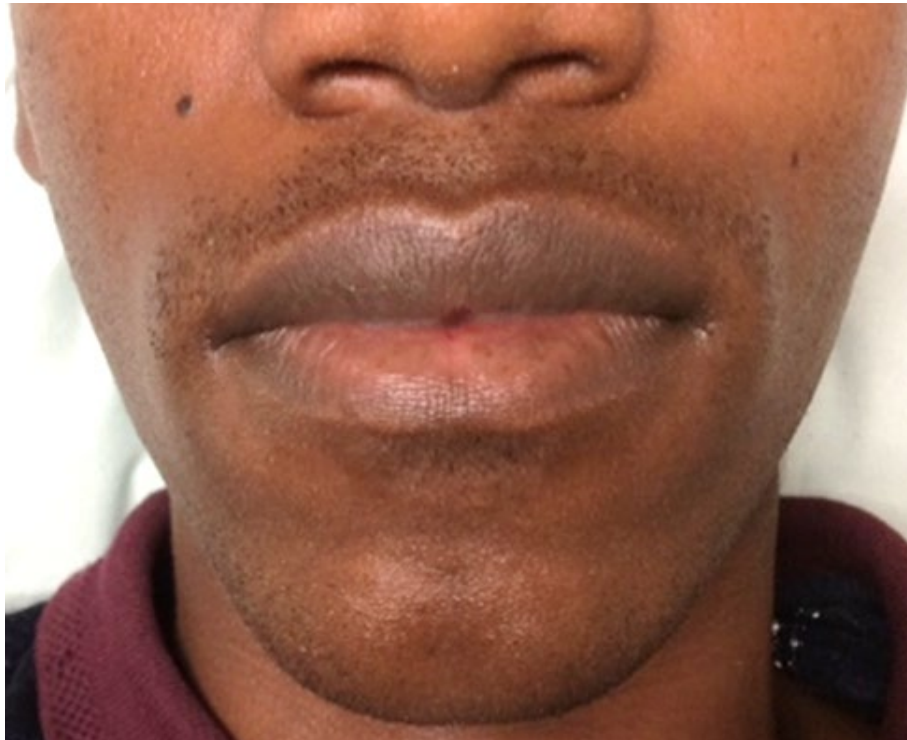**Dr. Matsidiso Moyaba , Polokwane, South Africa**

**Patient**

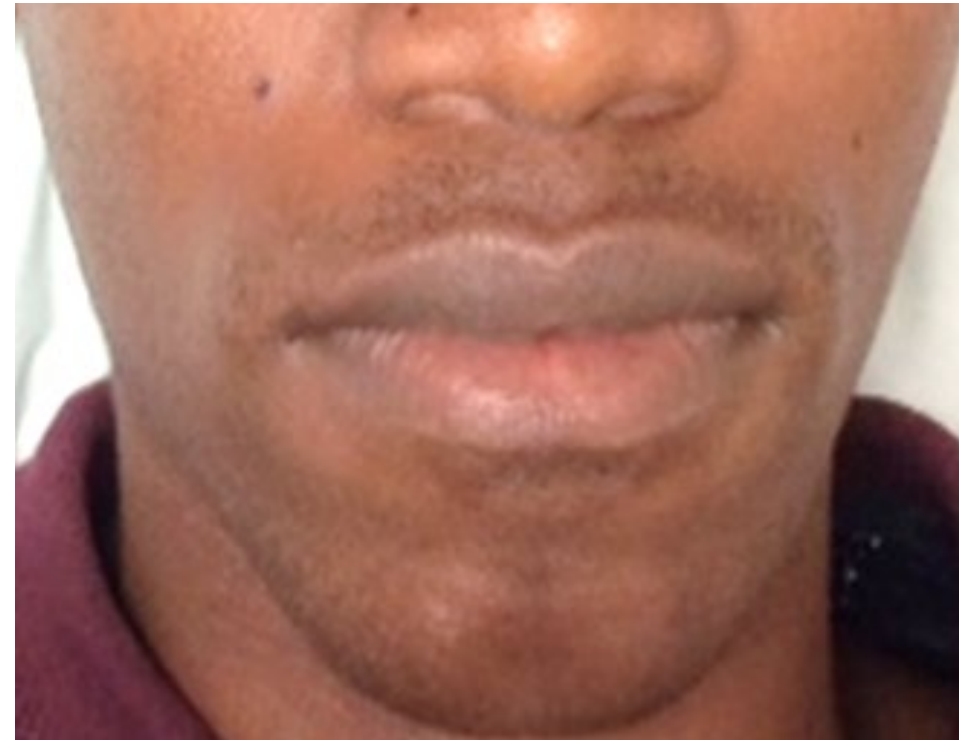Male, 22 years old (Fitzpatrick type V)

**Number of Treatments**

**2 V-Nd:YAG** (Single, 30 J/cm<sup>2</sup>, 25 ms, 9.5 mm spot size)




Before



After



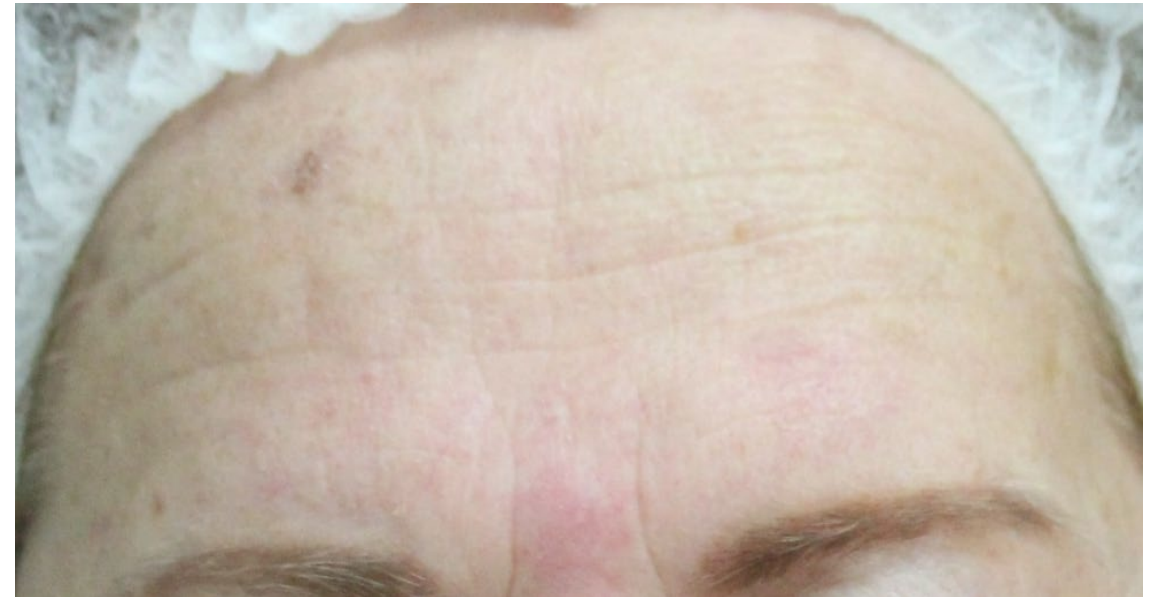
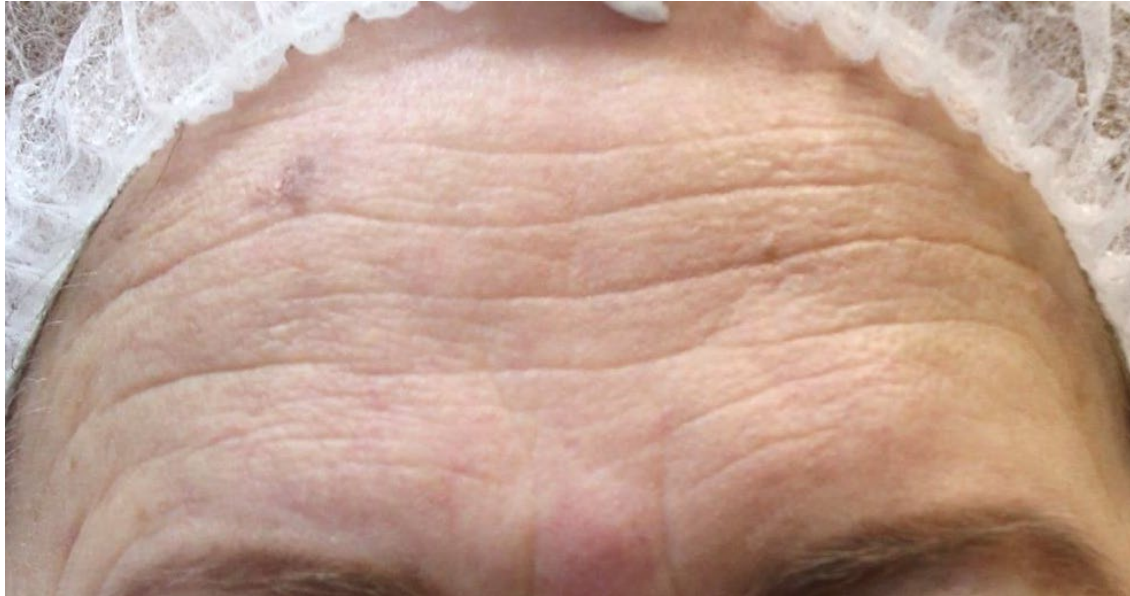
# Skin Rejuvenation



# Facial Skin Rejuvenation

|                               |   |
|-------------------------------|---|
| <b>Case Study – VNd#017-A</b> | <b>Dr. Cruzy Tagger, Viora Ltd.</b>   |
| Patient                       | Female, 68 years old  |
| Number of Treatments          | <b>1 V-Nd:YAG</b> (9.5 mm spot size, 25-35 J/cm <sup>2</sup> , 25 ms, Single) |



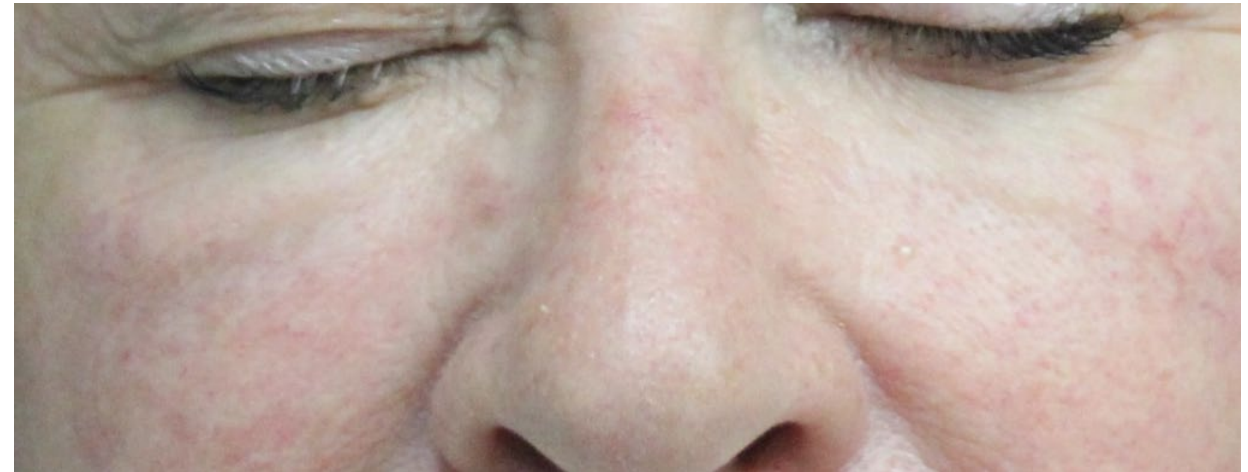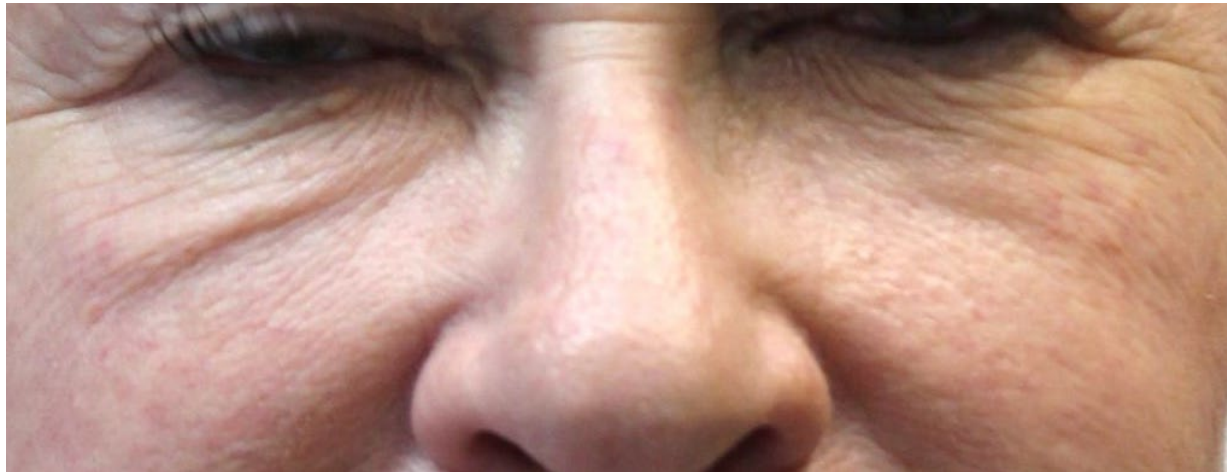Before

After



# Facial Skin Rejuvenation

|                               |   |
|-------------------------------|---|
| <b>Case Study – VNd#017-B</b> | <b>Dr. Cruzy Tagger, Viora Ltd.</b>   |
| Patient                       | Female, 68 years old  |
| Number of Treatments          | <b>1 V-Nd:YAG</b> (9.5 mm spot size, 25-35 J/cm <sup>2</sup> , 25 ms, Single) |



Before

1 month after



# Post-acne Scars

**Case Study – VNd#040-A**

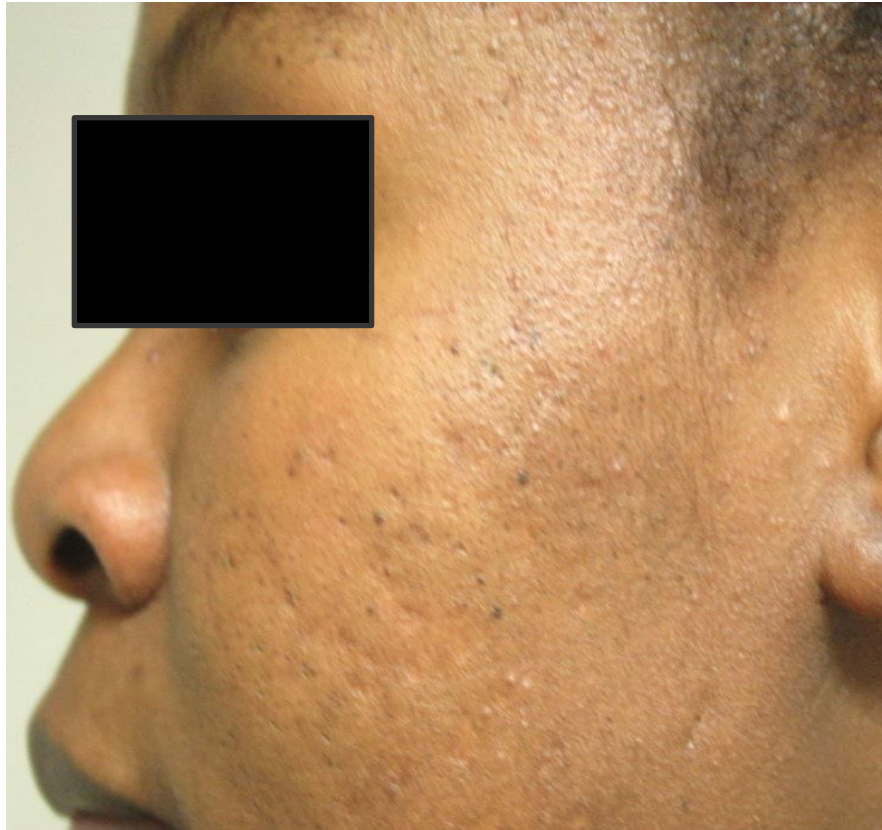**Dr. Matsidiso Moyaba , Polokwane, South Africa**

**Patient**

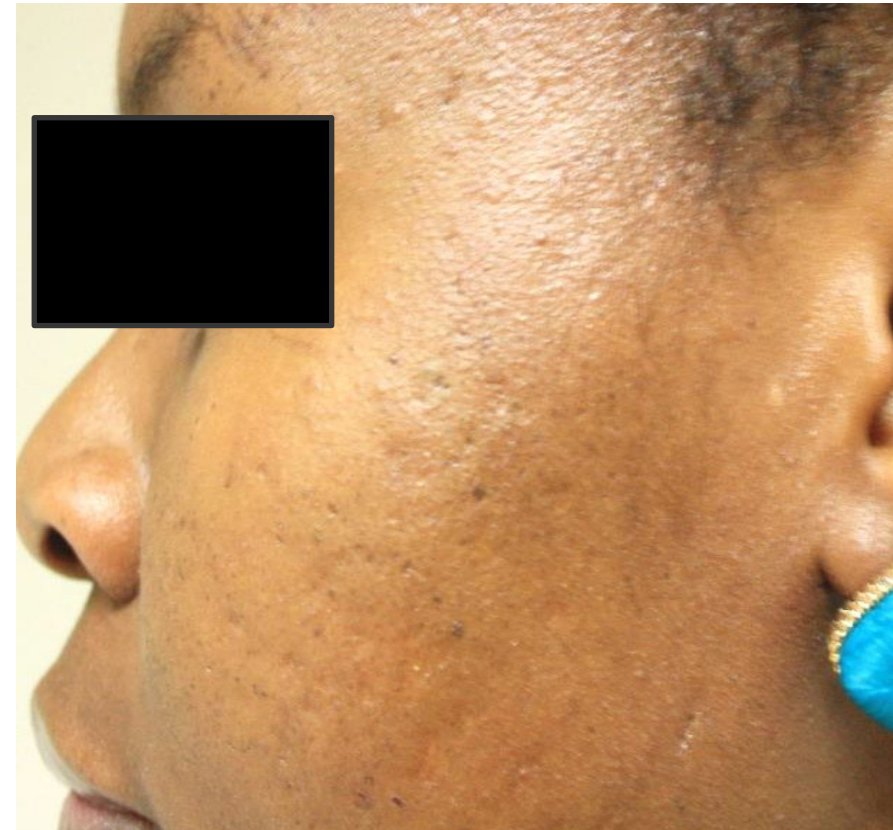Female, 22 years old (Fitzpatrick type VI)

**Number of Treatments**

**3 V-Nd:YAG (Multiple, 30 J/cm<sup>2</sup>, 9.5 mm spot size)**



**Before**



**After**



# Post-acne Scars

**Case Study – VNd#040-B**

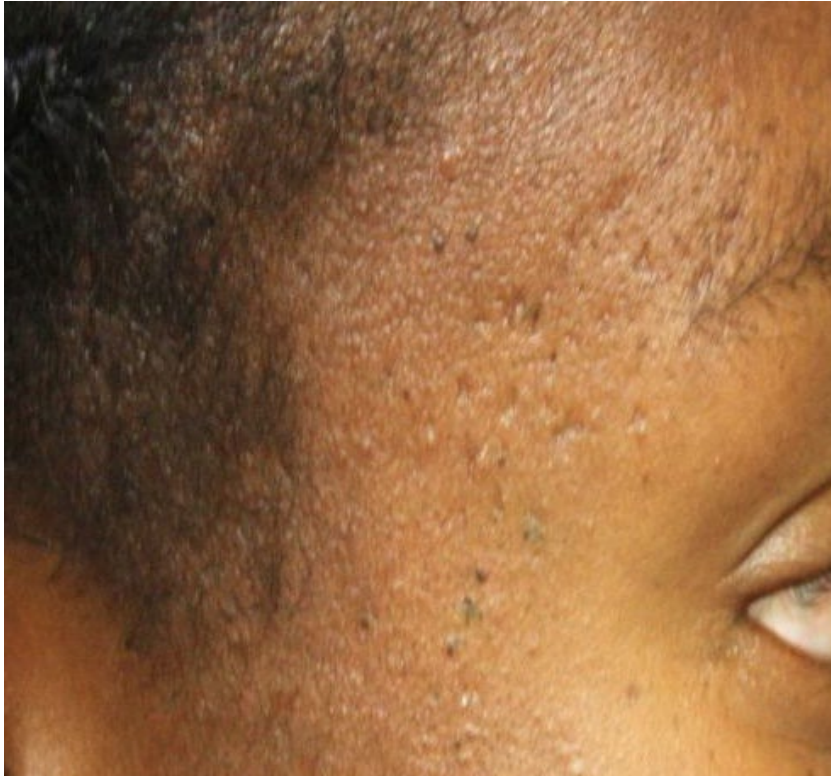**Dr. Matsidiso Moyaba , Polokwane, South Africa**

**Patient**

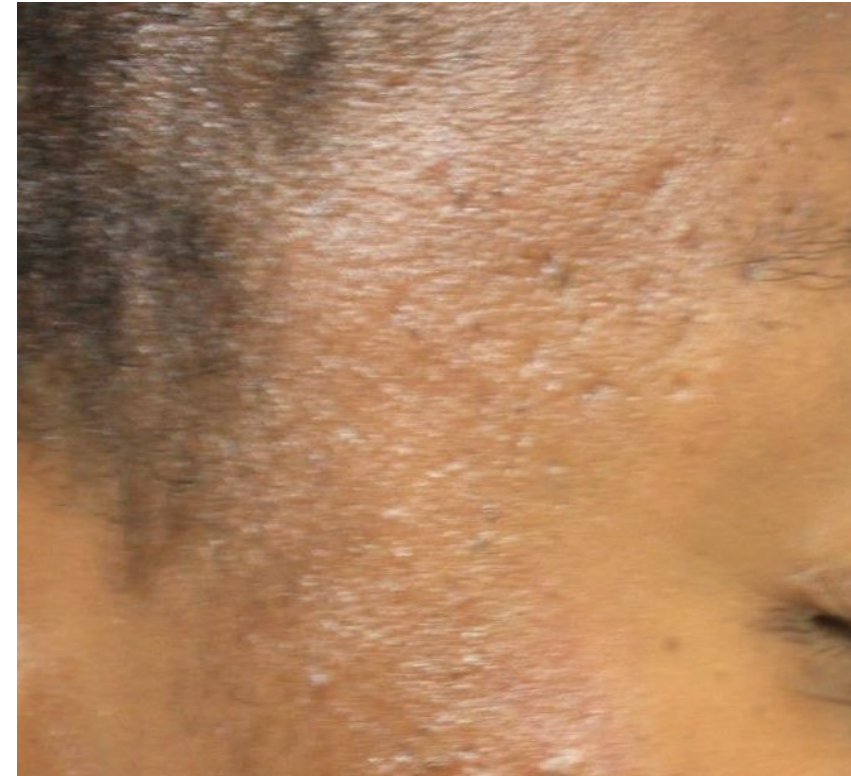Female, 22 years old (Fitzpatrick type VI)

**Number of Treatments**

**3 V-Nd:YAG (Multiple, 30 J/cm<sup>2</sup>, 9.5 mm spot size)**



**Before**

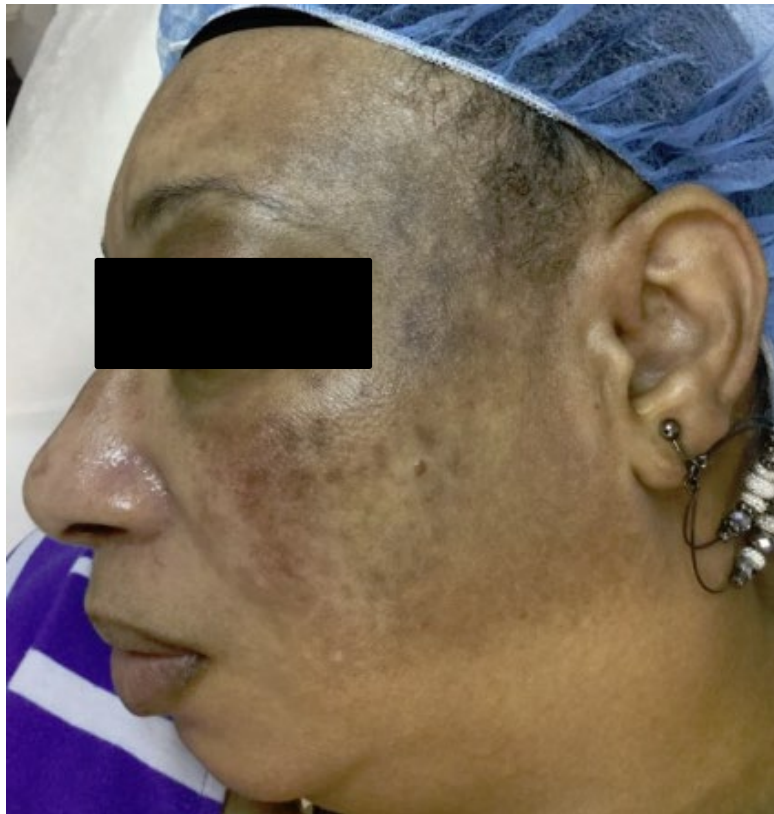

**After**

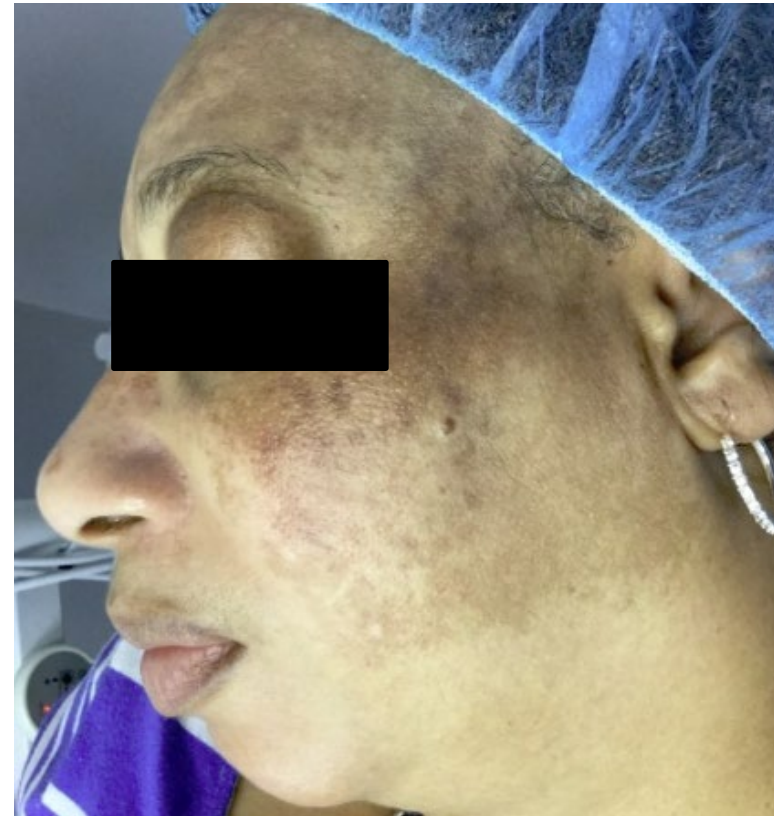

# Facial Skin Rejuvenation

|                             |  |
|-----------------------------|--|
| <b>Case Study – VNd#051</b> | <b>Dr. Angelo P. Thrower, Miami, FL, USA</b>                               |
| Patient                     | Female, 55 years old (Fitzpatrick V)                                       |
| Number of Treatments        | <b>2 V-Nd:YAG</b> (9.5 mm spot size, 35 J/cm <sup>2</sup> , 25 ms, Single) |



Before



8 weeks After





# Facial Acne Clearance

**Case Study – VNd#052-A**

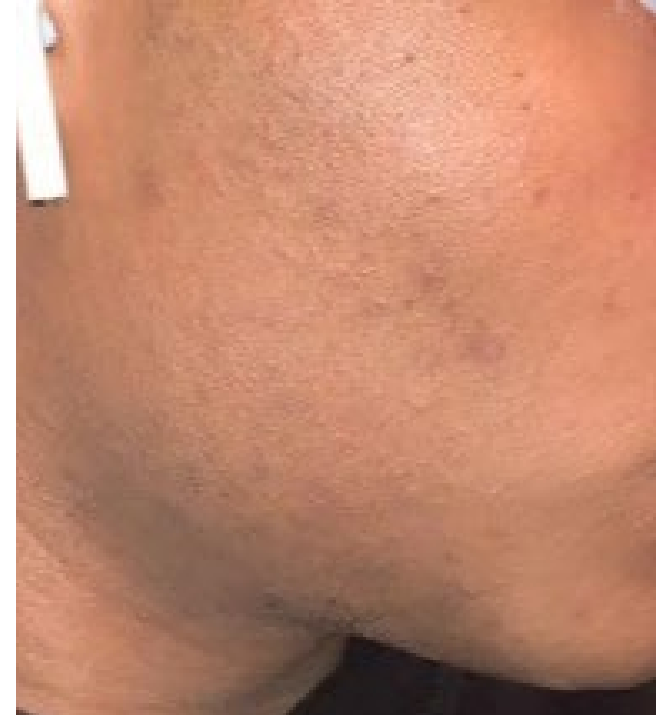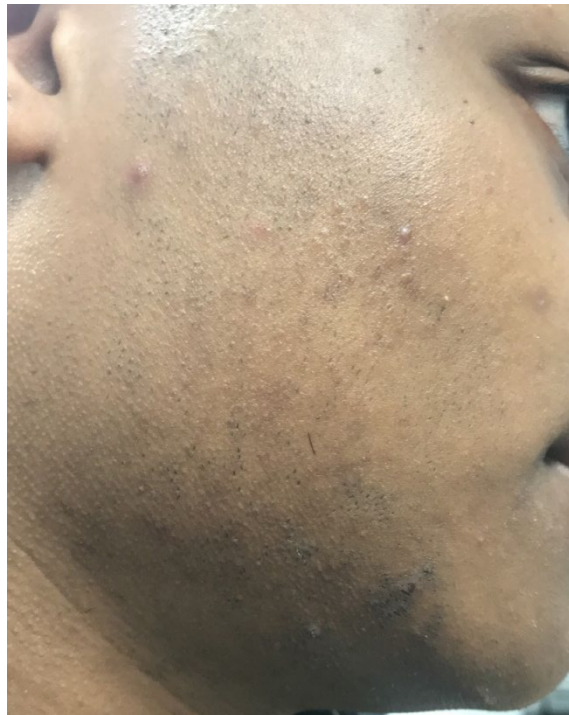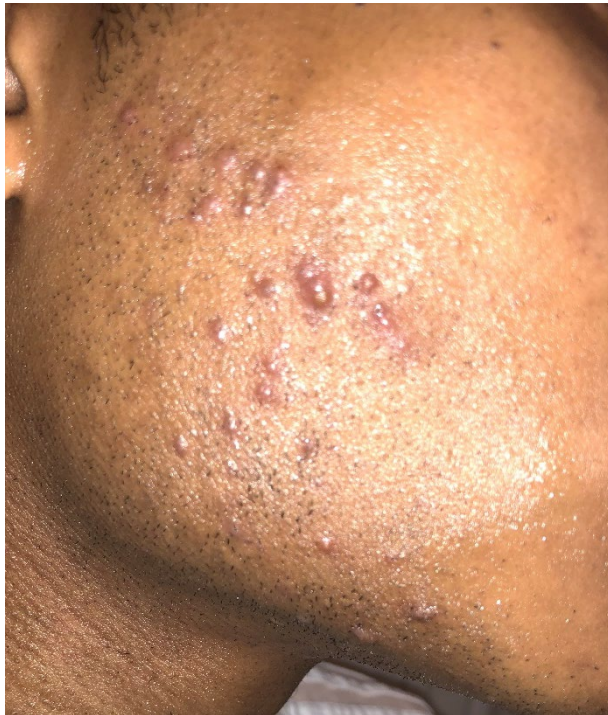**Dr. Angelo P. Thrower, Miami, FL, USA**

**Patient**

Male, 21 years old (Fitzpatrick type V)

**Number of Treatments**

**6 V-Nd:YAG** (Single, 30 J/cm<sup>2</sup>, 25 ms, 9.5 mm spot size)



**Before**

**3 months After**

**6 months After**



# Facial Acne Clearance

**Case Study – VNd#052-B**

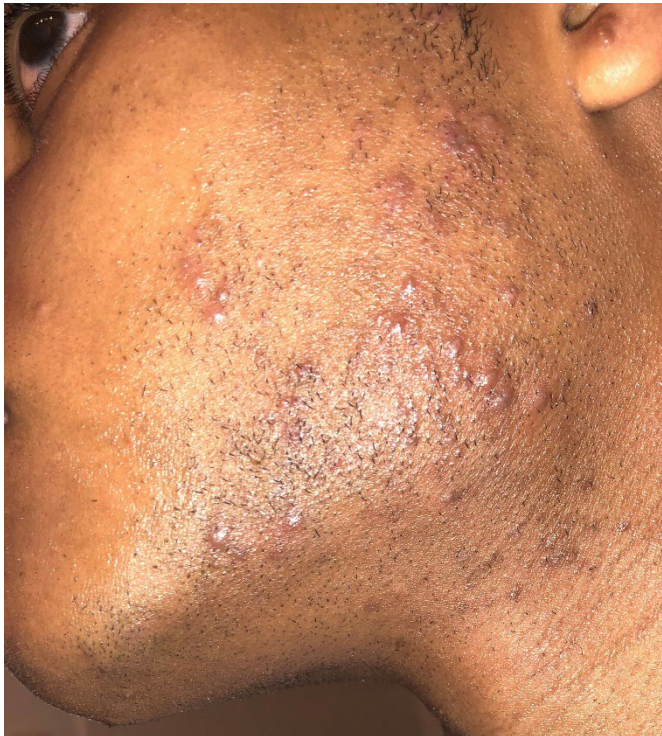**Dr. Angelo P. Thrower, Miami, FL, USA**

**Patient**

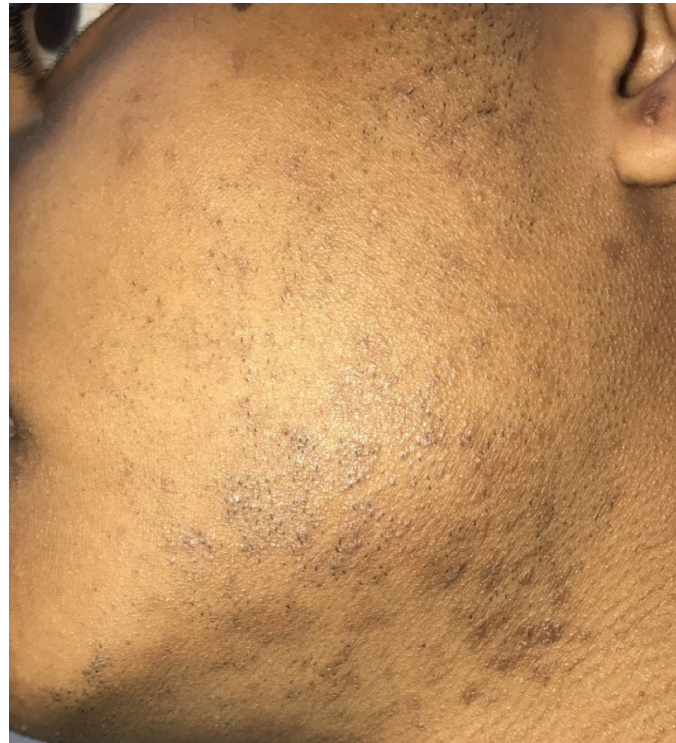Male, 21 years old (Fitzpatrick type V)

**Number of Treatments**

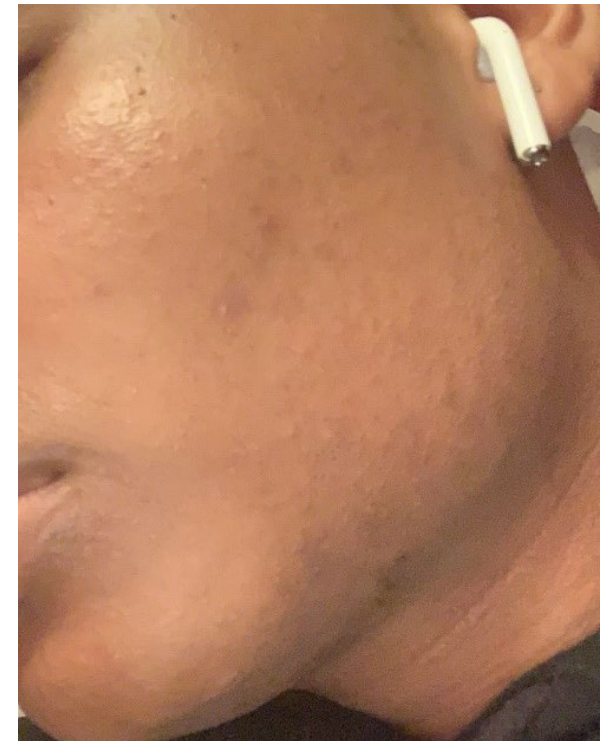
**6 V-Nd:YAG** (Single, 30 J/cm<sup>2</sup>, 25 ms, 9.5 mm spot size)



**Before**



**3 months After**

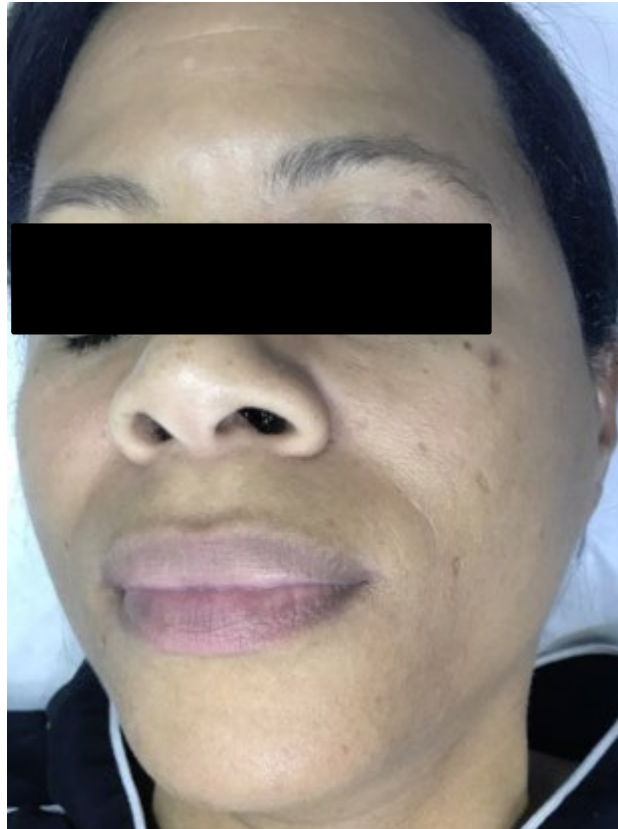


**6 months After**

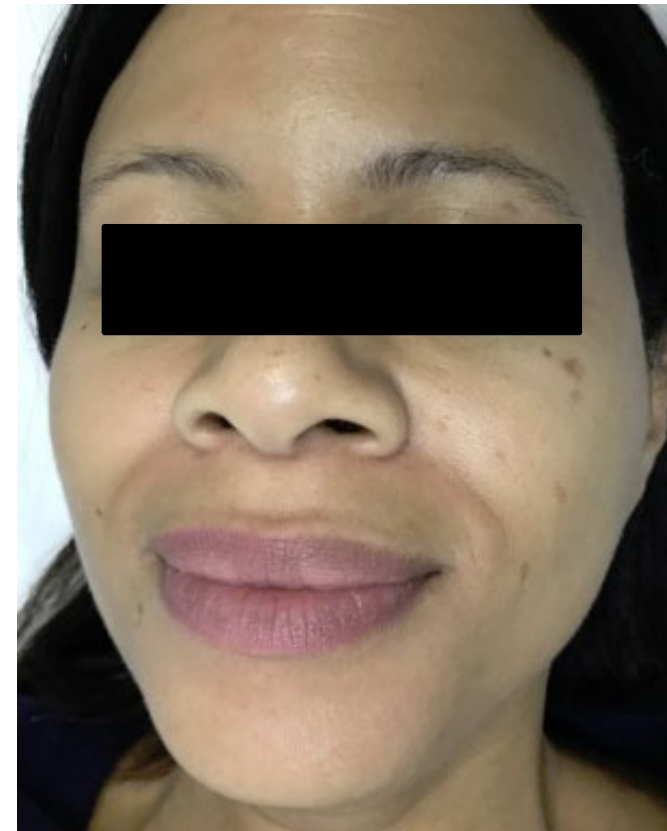

# Facial Skin Rejuvenation

|                             |  |
|-----------------------------|--|
| <b>Case Study – VNd#053</b> | <b>Dr. Angelo P. Thrower, Miami, FL, USA</b>                               |
| Patient                     | Female, 47 years old (Fitzpatrick V)                                       |
| Number of Treatments        | <b>3 V-Nd:YAG</b> (9.5 mm spot size, 35 J/cm <sup>2</sup> , 25 ms, Single) |



Before



8 weeks After



# Thank You!

Questions? Comments?

